

# Pancreatic pseudocysts: effectiveness of endoscopic drainage procedures

**Elena Zdanytė,  
Kęstutis Strupas,  
Algimantas J. Bubnys,  
Aleksandras Uþkalnis**

*Centre of Abdominal Surgery, Vilnius  
University Santariøkiø Klinikos  
Hospital, Vilnius, Lithuania*

*Author for correspondence: Elena  
Zdanytė, VUL Santariøkiø klinikos,  
Santariøkiø 2, Vilnius, Lithuania.  
E-mail: Elena.Zdanyte@santa.lt*

Indications and contraindications for endoscopic drainage of pancreatic pseudocysts are still under discussion. The purpose of our study was to evaluate the efficacy of endoscopic drainage procedures, operative and early postoperative complications and to establish selection criteria to this procedure.

**Methods.** 32 patients (20 males and 12 females), mean age 46.97 years (range, 20–87) were managed by endoscopic drainage procedures from February 2000 to October 2004. Symptomatic and / or bigger than 6 cm pancreatic pseudocysts with a close opposition to gastroduodenal wall were drained by endoscopic route. Pseudocystogastrostomy or pseudocystoduodenostomy was performed by 5–60 mm incision in 13 cases and with cystonasal drain in 4 cases. There were 19 transmural drainage procedures with a double pigtail stent. One patient was treated by pancreatic duct sphincterotomy.

**Results.** 25 (78.8%) pseudocysts completely resolved. There were 6 bleeding episodes: endoscopic haemostasis was achieved in 5 cases, one patient underwent emergency operation. Six patients required subsequent operations because of gastric wall perforation (3), postoperative haemorrhage (1), or insufficient drainage (2).

**Conclusions.** Endoscopic drainage is an effective alternative to surgical treatment of pancreatic pseudocysts. Bleeding is the most frequent complication of endoscopic transmural drainage, and it is successfully managed by endoscopic haemostasis. Contraindications for this procedure are pseudocysts without close opposition to gastrointestinal wall, pancreatic head enlargement and / or pancreatic duct cutoff or dilation when pancreatic resection or duct drainage operations are indicated. Resection should always be performed in cases when the diagnosis of cystic neoplasm cannot be rejected.

**Key words:** pancreatic pseudocyst, pseudocystogastrostomy, pseudocystoduodenostomy, endoscopic drainage, effectiveness

## INTRODUCTION

Pancreatic pseudocysts are important sequelae of both acute and chronic pancreatitis and represent 80–90% of cystic lesions of the pancreas. Benign and malignant cystic neoplasms constitute 10–13%, congenital and retention cysts comprising the remainder (1, 2).

A pancreatic pseudocyst is a collection of pancreatic-enzyme-rich fluid originated in or adjacent to the pancreas and enclosed in a wall of granulation and / or fibrous tissue lacking an epithelial lining (3). Controversy exists regarding the relative merits of observation and interventional treatment. The timing and mode of intervention have yet to be definitively answered in clinical trials. The introduction of new treatment modalities has also increased the options

for surgical management. New minimally invasive endoscopic and laparoscopic approaches must be compared to the traditional surgical internal drainage (Roux-en-Y cystojejunostomy, cystogastrostomy, cystoduodenostomy) with a low morbidity, mortality and recurrence rates allowing a wide and permanent internal decompression of larger cysts and resection of smaller cysts, together with the underlying segment of diseased pancreas as necessary (4, 5). Endoscopic drainage provides a good alternative or supplement to a surgical treatment of pancreatic pseudocysts (6, 7). There are currently no randomized controlled studies to compare the various minimally invasive approaches in the management of pancreatic pseudocysts (8). The purpose of the current study was to evaluate the efficacy of endoscopic drainage procedures, operative and early postoperative complications,

to establish selection criteria to this procedure and to prepare for a randomised controlled trial.

## MATERIALS AND METHODS

Endoscopic drainage procedures performed from February 2000 to October 2004, details that related to the patient, pseudocyst, pancreatitis were prospectively collected, reviewed and evaluated. Peri-pancreatic fluid collections that were of less than 4 weeks' duration, abscesses were excluded from the study. Patients who were initially treated for a pseudocyst but later proved to have a cystic neoplasm or pancreatic cancer were excluded too.

33 procedures were performed for 32 patients. There were 20 males and 12 females, mean age 46.97 year (range, 20–87), most of them were from 30 to 60 years of age (Fig. 1).

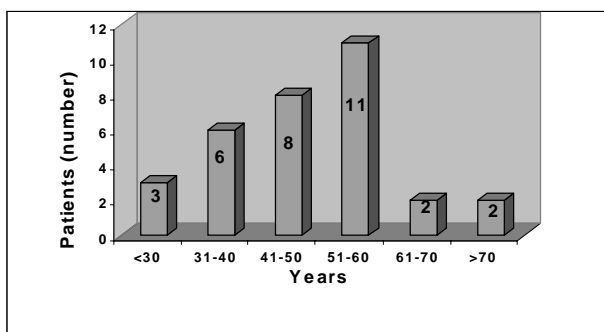


Fig. 1. Distribution of patients by age

Clinical signs and symptoms, the duration of time it has been present, pancreatitis attacks and etiology were recorded. Transabdominal and endoscopic ultrasound, CT scan and / or BMR were used to determine the number, size, volume, wall thickness, location of pancreatic pseudocysts, the extent of pancreatic parenchymal disease, the nature of the main pancreatic duct and its relationship to the cyst, the presence of portal hypertension, venous occlusion, arterial anomalies and pseudoaneurysms. Pseudocysts were classified according to the size (5–10 cm, >10 cm in major diameter), volume (<500 ml, 500–1000 ml, >1000 ml), location (pancreatic head, body and tail, within and adjacent to the pancreas) and etiology (acute and chronic). Procedure indications, peculiarities, complication rates, collection recurrence rates, early outcomes and long-term results were evaluated.

The indications for endoscopic drainage were symptomatic and / or bigger than 5 cm in major diameter pancreatic pseudocysts with a close opposition to the gastric or duodenal wall. The technique included endoscopic visualisation of the most prominent point bulging into gastric or duodenal lumen, puncture of the pseudocyst with a pre-cut knife, cannulation of the opening with a guidewi-

re followed by sphincterotomy to enlarge the communication, opacification of the pseudocyst with contrast agent to evaluate its possible communication with the pancreatic duct. Endoscopic ultrasound was used to identify the site of puncture, to evaluate wall thickness and to avoid occasional puncture of vessels interposed between the pseudocyst and bowel lumen in 21 (61.8%) cases. Endoscopic pancreatography was conducted in cases of a dilated or irregular main pancreatic duct to outline a possible pancreatic duct obstruction, anatomical anomaly and pseudocyst communication and to determine the possibility for transpapillary drainage. Pseudocystogastrostomy or pseudocystoduodenostomy was performed by increasing an opening to 0.5–6 cm in 14 cases, transmural drainage with 3–6 cm 7 or 10 Fr double pigtail endoprosthesis in 17 cases and cystonasal drain in 4 cases. One pseudocyst was treated by pancreatic duct sphincterotomy.

## RESULTS

There were 33 pseudocysts diagnosed in 32 patients; 31 patients had solitary pseudocysts and 1 patient had two. The pseudocysts were located in the head / neck ( $n = 7$ ), body ( $n = 21$ ) and tail of the pancreas ( $n = 5$ ) (Fig. 2).

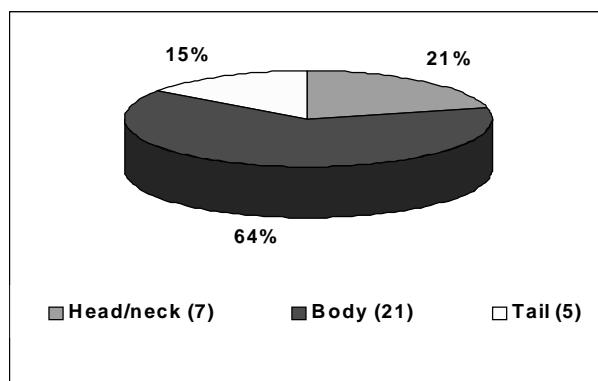


Fig. 2. Location of pseudocysts

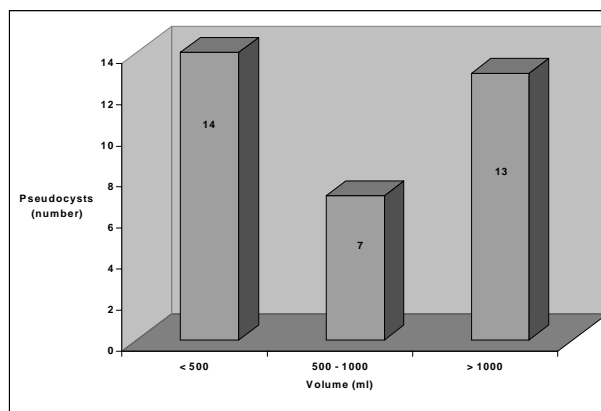


Fig. 3. Distribution of pseudocysts by volume

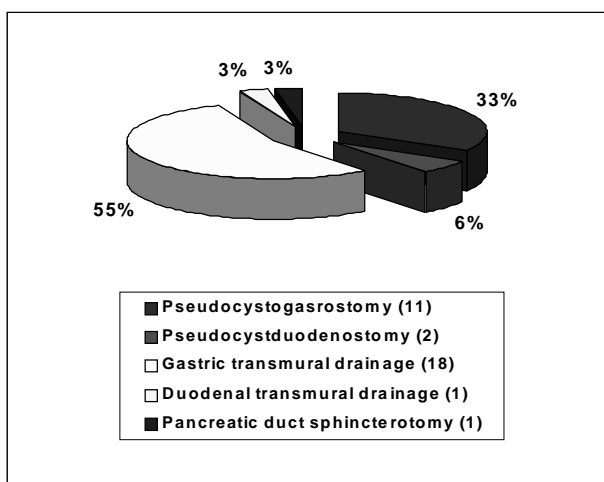


Fig. 4. Types of endoscopic drainage procedures

The mean size was 11.46 cm (range, 6–22) and the mean volume 863.96 ml (range, 250–5000) (Fig. 3). The mean wall thickness was 5.04 mm (range, 2.2–8).

There were 33 endoscopic drainage procedures: 11 pseudocystogastrostomies and 2 pseudocystoduodenostomies (length range from 5 to 60 mm). Gastric transmural drainage was performed in 18 cases, duodenal transmural drainage in 1 and pancreatic duct sphincterotomy in 1 case (Fig. 4).

Complete endoscopic resolution was achieved in 25 patients (78.1%). Three patients with suppurated pseudocysts were treated by continuous saline irrigation through cystonasal drain from 6 to 21 (mean 13.67) days. In one case second stent was inserted because of insufficient drainage.

There were six bleeding episodes during endoscopic drainage. Endoscopic haemostasis was achieved by adrenalin solution (1:10000) injection and / or electrocoagulation in 5 clinically insignificant cases. One patient underwent emergency operation (pseudocystogastrostomy). Two bleeding episodes developed 12 hours after the procedure. One patient was treated endoscopically and another was operated on emergency basis and ruptured pseudoaneurysm undiagnosed before the endoscopic procedure was found.

There were three emergency operations because of gastric wall perforation. There were no clear impression of the stomach wall during endoscopy and there were no possibility to use endoscopic ultrasound, so free gastric wall was perforated in two cases. In another case separated gastric and pseudocyst walls were found during emergency operation.

One impacted stent was successfully extracted after incision enlargement. One patient recovered only after pancreatic head resection and another after pseudocystojejunostomy because of insufficient endoscopic drainage in the cases of chronic pancreatitis.

## DISCUSSION

Large pancreatic pseudocysts in particular were related with complications such as bleeding, rupture, abscess, or fistula in up to 55% of cases (9). These large cysts over 5 cm and every cyst causing symptoms require treatment. In our series all endoscopically treated pseudocysts fit these criteria. Traditionally, pseudocysts requiring drainage have been managed surgically, either externally or internally. Percutaneous catheter drainage under radiologic guidance is reported to be a valuable adjunct or alternative to operative pseudocyst management. It has been used with increased frequency over the past decade, but fistulous tract formation, infection, increased morbidity and mortality have been reported by the critics (10, 11). We prefer different modalities of internal pseudocyst drainage. Results of endoscopic drainage are generally good, with a technical success rate between 80 and 90% for transmural pseudocystogastrostomy and pseudocystoduodenostomy and almost 85% for transpapillary methods (12). Transmural drainage through the stomach or duodenal wall requires the following conditions: (1) the stomach or duodenal wall must share a common wall with pseudocyst (2), the distance between the pseudocyst and the gastric wall must be < 1 cm on preoperative investigations; (3) there must be a clear impression of the wall of the stomach or duodenum at endoscopy; (4) absence of varices; (5) it is imperative that the cyst structure is not a neoplasm or a pseudoaneurysm (12). In our study, 25 (78,1%) pseudocyst resolved after endoscopic drainage procedures. There were three cases of gastric wall perforations – there were no clear impression of the stomach wall during endoscopy and there were no possibility to use endoscopic ultrasound in two cases and separated gastric and pseudocyst walls were found during emergency operation in the third case.

There were more complications during the first 15 procedures. Better results were achieved after meticulous patient selection and because of growing experience.

## CONCLUSIONS

Endoscopic drainage is an effective alternative to surgical treatment of pancreatic pseudocysts (PPCs). Bleeding is the most frequent complication of endoscopic transmural drainage of PPCs; it is successfully managed by endoscopic haemostasis. Contraindications for this procedure are pseudocysts without close opposition to gastrointestinal wall, pancreatic head enlargement and / or pancreatic duct stricture, duct cutoff or dilation (>6 mm) when pancreatic resection and / or duct drainage operations are indicated. Better results can be achieved by meticulous patient selection. Pancreatic resection should always be

performed in cases when the diagnosis of cystic neoplasm cannot be rejected. Endoscopic drainage permits to avoid external fistula formation in cases of suppurated pancreatic pseudocysts.

Received 20 September 2004

Accepted 15 October 2004

## References

1. Fernandez-del Castillo C, Warshaw AL. Cystic tumours of the pancreas. *Surg Clin North Am* 1995; 75: 1001–16.
2. Hamilton SR, Aaltonen LA (Eds.): *World Health Organization Classification of Tumours: Pathology and Genetics of Tumours of the Digestive System*. IARC Press: Lyon 2000.
3. Bradley EL. A clinically based classification system for acute pancreatitis: summary of the international symposium on acute pancreatitis. Atlanta, GA, September 11–13, 1992. *Arch Surg* 1993; 128: 586–90.
4. Usatoff V, Bracatisano R, Williamson RCN. Operative treatment of pseudocysts in patients with chronic pancreatitis. *Br J Surg* 2000; 87: 1494–9.
5. Grace PA, Williamson RCN. Modern management of pancreatic pseudocysts. *Br J Surg* 1993; 80(5): 573–81.
6. Beekingham IJ, Krige JEJ, Bornman PC, Terblanche J. Long term outcome of endoscopic drainage of pancreatic pseudocysts. *AJG* 1999; 94(1): 71–4.
7. Vitale GC, Lawhon JC, Larson GM, Harrel DJ, Reed DN, MacLeod S. Endoscopic drainage of the pancreatic pseudocyst. *Surgery* 1999; 126(4): 616–23.
8. Bhattacharya D, Ammori BJ. Minimally invasive approaches to the management of pancreatic pseudocysts. *Surg Laparosc Endosc Percutan Tech* 2003; 13(3): 141–8.
9. D'Egidio A, Schein M. Pancreatic pseudocysts: a proposed classification and its management implications. *Br J Surg* 1991; 78: 981–4.
10. Saeed OM, Casillas J, Sheikh M. Percutaneous catheter drainage of pancreatic pseudocysts: five years experience. *Med Principles Pract* 2001; 10: 89–92.
11. Adams DB, Srinivasan A. Failure of percutaneous catheter drainage of pancreatic pseudocyst. *The American Surgeon* 2000; 66(3): 256–61.
12. Rosso E, Alexakis N, Ghaneh P, Lombard M, Smart HL, Evans J, Neoptolemos JP. Pancreatic pseudocyst in chronic pancreatitis: endoscopic and surgical treatment. *Dig Surg* 2003; 20: 397–406.

**E. Zdanytė, K. Strupas, A. J. Bubnys, A. Uškalis**

## KASOS PSEUDOCISTOS: ENDOSKOPINIO DRENAVIMO EFEKTYVUMAS

### Santrauka

**Āvadas.** Gerėjanti diagnostika, etiopatogenezės supratimas, nauji minimalios invazijos gydymo metodai keičia kasos pseudocistø gydymo taktikà. Nėra atlikta randomizuotø studijø, palyginanėiø àvairius gydymo metodus. Kasos pseudocistø endoskopinio drenavimo indikacijos ir kontraindikacijos nėra tiksliai apibrėžtos. Darbo tikslas buvo išnagrinti endoskopinio kasos pseudocistø drenavimo efektyvumą, intraoperacines ir ankstyvas pooperacines komplikacijas bei jø priežastis.

**Metodai.** Nuo 2000–2004 m. 32 ligoniams kasos pseudocistos drenuotos endoskopiškai. Transabdominalinės ir endoskopinės sonoskopijos, kompiuterinės tomografijos, branduolinio magnetinio rezonanso tyrimais nustatyti pseudocistø morfologiniai požymiai, galintys turėti àtakos gydymo rezultatams. Àvertinta àvairiø tyrimø reikėmė nustatant endoskopinio drenavimo indikacijas. Endoskopiškai drenuotos simptominės ir/arba didesnės nei 6 cm skersmens pseudocistos, turinėios bendrà sienelà su skrandžiu arba dvylikapiršte žarna. Trylikai ligoniø atlikta endoskopinė pseudocistogastrotomija arba pseudocistoduodenostomija, 19 ligoniø – transmuralinis drenavimas dvigubos „J“ formos stentu, vienam – papilofinkterotomija ir virsungotomija. Keturiems ligoniams pseudocistos ertmė drenuota à išorà cistonazaliniu drenu.

**Rezultatai.** Dvidešimt penkiems (78,1%) ligoniams endoskopinis gydymas buvo efektyvus. Dažniausia intraoperacinė komplikacija – kraujavimas. Keturiems ligoniams kraujavimas iš punkcijos ar àpjovos vietos sustabdytas injekcine hemostaze arba elektrokoaguliacija, vienas ligonis operuotas skubos, vienas – planine tvarka. Trims ligoniams buvo perforuota skrandžio sienelė ir patekta à laisvà pilvø ertmė. Dėl nepakankamo drenavimo 5 ligoniams atliktos papildomos endoskopinės procedūros, 2 operuoti atviru būdu.

**Išvados.** Endoskopinis pseudocistø drenavimas – efektyvus kasos pseudocistø gydymo būdas tikslingai atrinktai ligoniø grupei. Kraujavimas – dažniausia intraoperacinė komplikacija, sėkmingai gydoma endoskopine hemostaze. Kontraindikacijos – pseudocistos ir gastrooduodeninės sienos vientisumo nebuvimas, kasos parenchimos ir / arba latako patologija, kai būtina kasos rezekcinė arba latakà drenuojanti operacija. Jei negalima paiegti kasos cistinės neoplazmos diagnozės, indikuotina rezekcinio tipo operacija.