

Beheading in Avar times (630–800 A.D.)

**Karin Wiltschke-Schrotta¹,
Peter Stadler²**

¹ Dept. of Anthropology,
Natural History Museum Vienna,
Austria

² Dept. of Prehistory,
Natural History Museum Vienna,
Austria

Address for correspondence:
Karin Wiltschke-Schrotta,
Dept. of Anthropology,
Natural History Museum Vienna,
Burgring 7, 1010 Vienna, Austria
e-mail karin.wiltschke@nhm-wien.ac.at

The cause of an individual's death is a frequent question when we investigate human skeletal remains. Unfortunately, in most cases the cause of death is impossible to determine. However, while investigating an Avar period population (630–800 A.D.) with 540 burials from Mödling Goldene Stiege, Austria, three individuals with sharp cut marks at the cervical vertebrae were identified. The aim of this study was investigation of the possibility that these individuals were beheaded. **Materials and methods.** Description and discussion of the cut marks, archaeological findings such as tools or weapons in connection with the site, as well as an examination of the social status of the individuals within the population. **Results and discussion.** Two of the three individuals seem to be regularly beheaded from the back, probably with an axe and the head fixed on a block. The third individual might have been stabbed by a smaller weapon, like a knife, without complete separation of the head. One male was of high status, the two others were rather poor with grave goods. The person that was probably stabbed, with solely a knife as a grave good, had a very unusual prone burial position. **Conclusion.** Different cut marks on the cervical vertebrae and the social differences of these three males give the impression of beheading out of different motives. In general, decapitation does not seem to be a frequently used rite within the Avar period people of Austria.

Key words: Avar period, decapitation, cut marks

INTRODUCTION

Information concerning a possible cause of death is rarely seen on the skeleton. Cut marks may give clues on the way a person died, but they could also be traces of *post mortem* treatments. To find cut marks, the relevant bones have to be in good condition, and the investigator should be trained in detecting them. Cut marks on the cervical vertebrae – most probably for severing the head – can be found throughout all time periods. In prehistoric times these findings are frequent in connection with unusual burial situations. From the two pits in the Ofnet cave in Bavaria, Germany, from Mesolithic times (ca. 6.500 BC), skeletal parts from 38 individuals were found and 13 vertebrae show cut marks, mostly on their ventral surfaces (1, 2, 3). In Falkenstein, Austria, a Bronze Age period (1.700 BC) pit with parts of at least 9 individuals was found. Several cervical vertebrae show cut marks or were destroyed by sharp and heavy blows (4, 5). In Antiquity, especially in the Late Romano-British Period, more than 70 cemeteries with beheaded individuals are known and published (6–9). In the *Digesta* of Justinian (*Liber XLVIII*, Dig.48.19.28) the penalty of decapitation is mentioned as one capital punishment.

The Romans and the Greeks considered beheading a less dishonourable (and less painful) form of execution than other methods in use at the time. The Roman Empire used beheading for its own citizens whilst crucifying others (10). So far, in Austria no decapitated individual from the Roman Period has been unearthed.

For the Early Middle Ages in Central Europe (350–1000 A.D.) the anthropological evidence for beheading is rare. In Austria many burial sites of Avar people (630–800 A.D.) have been studied by physical anthropologists, but no cut marks on the cervical vertebrae were mentioned (11–16). Fettich (17) interpreted the irregular position of the body of six individuals within the grave in an Avar period graveyard from Hungary as executions, but did not mention any cut marks on the bones. Among the Slavic people of Gars-Thunau (830–900 A.D.), four individuals with cut marks on the cervical vertebrae were found (information in courtesy of M. Teschler-Nicola). Later in history, paintings and written documentation give evidence of this widely used way of punishment. Beheading was usually reserved as a mode of executing offenders of high rank.

From the fifteenth century onwards, the victims of the axe include some of the highest personages

in the British kingdom (18). Beheading was used in Britain up to 1747 and was a standard method in Norway (abolished 1905), Sweden (up to 1903), Denmark and Holland (abolished 1870), and was used for some classes of prisoner in France (up until the introduction of the guillotine in 1792) and in Germany up to 1938. China also used it widely, until the communists came to power and exchanged it with shooting in the twentieth century. Japan used beheading up until the end of the nineteenth century too, prior to turning to hanging.

Thus, beheading was widely used in Europe and Asia until the 20th century, but now it is confined to Saudi Arabia, Qatar, Yemen and Iran. Saudi Arabia publicly beheaded 52 men and one woman for murder, rape, sodomy and drug offences in 2003 (10). Sadly, today beheading of foreigners in Iraq is a cruel daily method of terrorists blackmailing western countries (19).

MATERIALS AND METHODS

The burial ground of Mödling Goldene Stiege, Lower Austria, was excavated from 1967 to 1973. 540 skeletons were recovered and are more or less well preserved. 207 males and 180 females were anthropologically identified (20) using multiple sex and age indicators (21, 22). In addition, data from archaeological sexing by grave goods were included. 232 subadult skeletons were aged using dental development (23) and diaphyseal length (24). Body height was calculated using the correlation formulas for all ethnic groups from Sjøvold (25). Besides the usual anthropological investigations, a detailed palaeopathological analysis was undertaken (26), and the focus was set on pathological changes in the vertebrae. During this survey three individuals with cut marks on their cervical vertebrae were discovered. They were investigated macroscopically, with a magnifying lens (10x) and an Olympus stereomicroscope.

RESULTS

Case 1: Ind. 203

The skeleton of a 30–40-year old, probably male, skeleton was found in an unusually prone burial position. The body height was calculated as 166 cm. The surface of the bone is strongly eroded and the skeleton shows osteoarthritic changes on the vertebrae, knee, elbow and shoulder joints. The left mandibular joint displays osteoarthritic changes with an eburnated surface. A small osteoma can be detected on the frontal bone.

The first cervical vertebra has a small lesion on the lower surface of the left arch (Fig. 1). C2 shows a complete cut through the left upper intervertebral joint and body, crossing the dens axis in a transver-

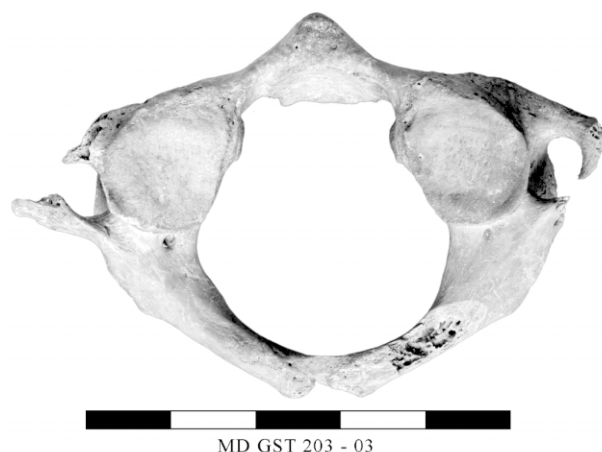

Fig. 1. Atlas with a cut mark lower surface of the left arch (Ind. 203)

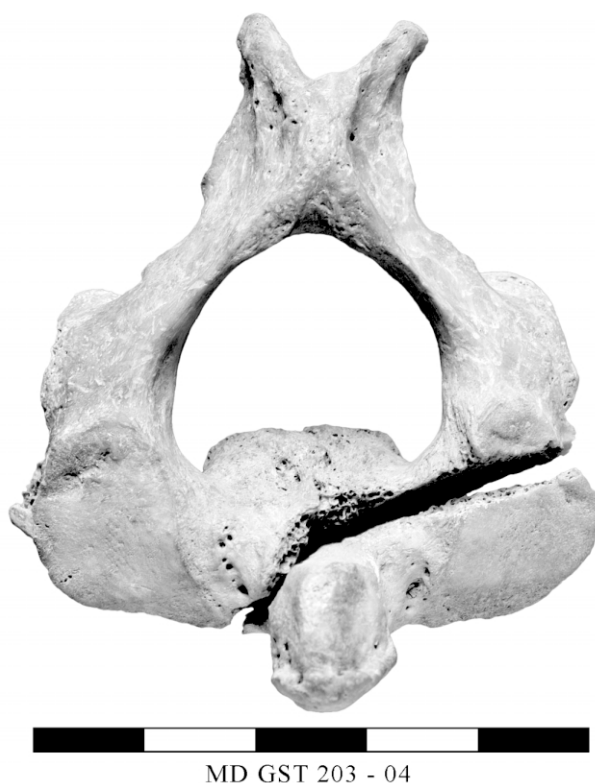
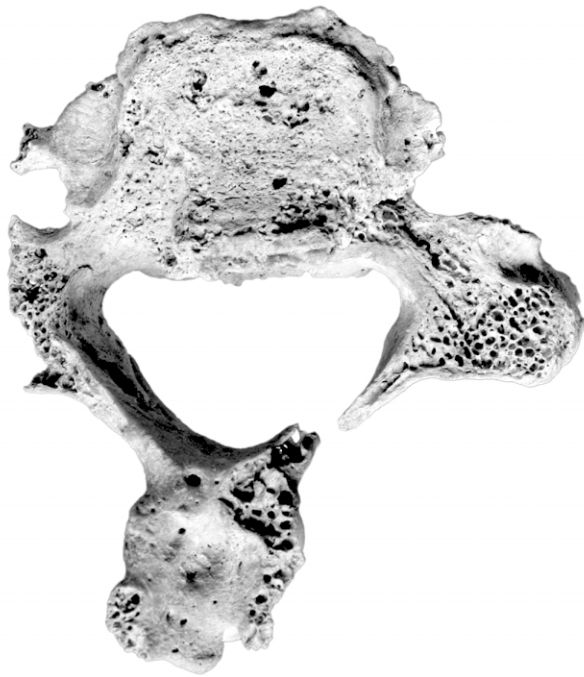
Fig. 2. Axis showing a cut mark of a sharp weapon penetrating from the left side (Ind. 203)

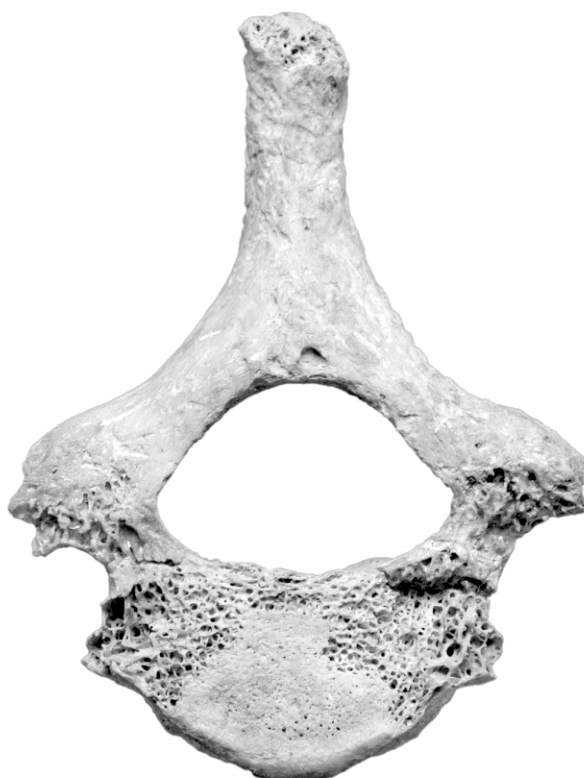sal angle from the lower front to the upper back, entering from the left. In the middle of the body the traces of the sharp-bladed instrument diminish and the rest of the body seems to be broken off (Fig. 2). The cuts on C1 and C2 originated from the same incident.

The base of C5 displays strong artrothitic changes. The left side of the arch shows the penetration of a sharp instrument from the transverse process to the body (Fig. 3). The attack probably chipped off the lower part of the arch. Only two fragments from C6 are available, and the left upper intervertebral joint too shows slight traces of a sharp cut.



MD GST 203 - 08

Fig. 3. 5th cervical vertebrae from distal with strong osteoarthrotic changes and a cut mark on the left transverse process and arch (Ind. 203)



MD GST 334 - 04

Fig. 4. 7th cervical vertebrae from proximal with traces of a sharp cut (Ind. 334)

Obviously the cuts were performed from the front with a sharp weapon. The attacked person was standing or lying. The weapon of the offender was not strong enough to penetrate through the complete vertebral column. Possibly a knife was used, and the individual was stabbed with it; certainly it happened twice from the left side and was carried out by a person who was probably right-handed. The head was probably not completely decapitated, as the cuts did not penetrate all the way through. This would explain why the head was not disarticulated within the grave.

Case 2: Ind. 334

The skeleton of this 25–40-year old male was found in a proper burial position, lying on the back with the arms aside. The estimated body height is 166 cm. Slight osteoarthritis is seen on the vertebrae, Schmorl's nodes are seen on the thoracal and lumbar vertebrae. Degenerative forces changed the bones of hands and feet.

Cut marks are visible on the 6th and 7th cervical vertebrae. The cut destroyed the lower part of C6 and the upper intervertebral joints and parts of the body of C7 (Fig. 1). One distinct cut is visible (Fig. 2). The traumatic input was performed with a sharp object applied at a right angle to the vertebral column. It seems that one single stroke from behind caused the damage. The location of beheading between C6 and C7 is rather uncommon. But the 7th cervical vertebra is a landmark in the vertebral column and possibly helped for orientation. For executing such a distinct cut from behind the head was possibly fixed on a block face down. With a single stroke the head was decapitated. As the cut goes all the way through the vertebral column a complete beheading is likely. Nevertheless, the head was buried in proper anatomical position, and the individual got a regular burial with proper grave goods.

Case 3: Ind. 485

An adult male aged 25–35 years with a body height of 173 cm is the third case with cut marks on cervical vertebrae. This individual had many stomatological problems such as dental crowding, dental calculus, enamel hypoplasia, abscesses and periodontal disease with a maxillary sinusitis.

Like Case two, the seventh cervical vertebra shows traces of a sharp cut on the upper surface, exposing the underlying trabecular bone (Fig. 6). Only a fragment of C6 is present.

Similarly Case two, the penetration of a sharp weapon came from behind, this time with a slight angle to the right (Fig. 4). Again, the cut severed the complete vertebral column and a complete beheading could be possible. The individual was buried regularly with the head in correct anatomical position.

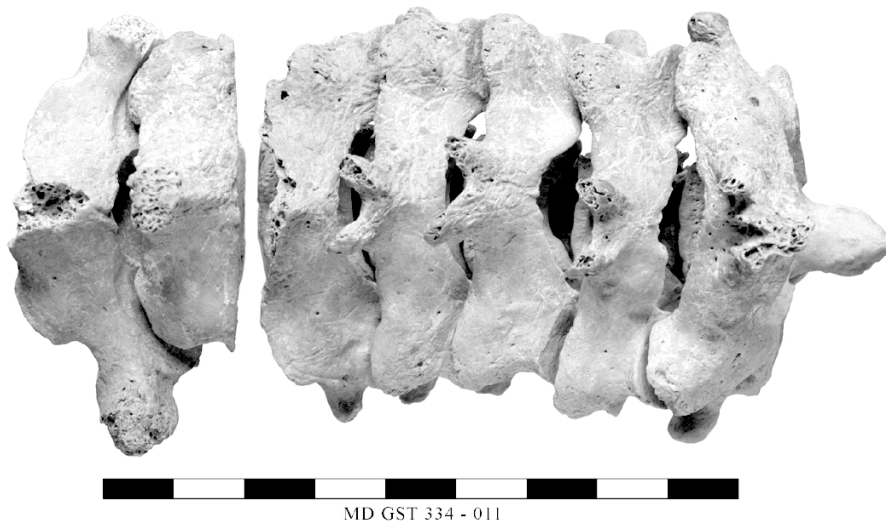


Fig. 5. The assembled vertebral column from dorsal showing a horizontal cut through C6 and C7 (Ind. 334)

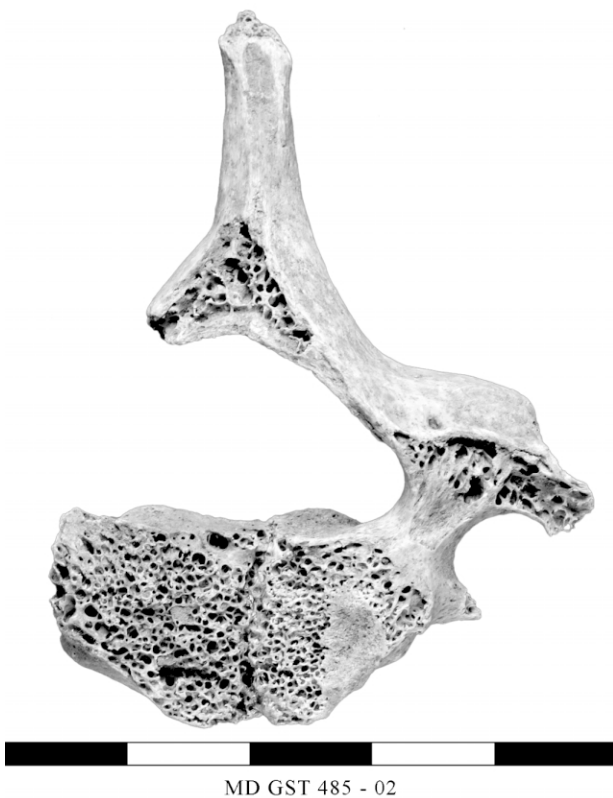

Fig. 6. 7th cervical vertebrae from proximal with traces of a sharp cut (Ind. 485)

DISCUSSION

We have to keep in mind that it is impossible to distinguish between a blow causing death by decapitating and a blow that removes the head shortly after death. For interpreting whether the rite of decapitation involved a living person or was the mutilation of a dead corpse, other facts such as the posture of the body in the grave or the way the cuts are located have to be taken into account. Grave position, grave

furniture, grave layout and the context of the graves within the burial site may give further information on some (7). In the presented cases, no connections concerning the position of the grave within the graveyard can be seen. All three burials are located differently within the graveyard and are situated irregularly within the other 537 burials. The grave furniture varies from case to case. The prone burial of individual 203, for example, has just a broken knife as a grave good. The man from grave 485 is buried regularly and has a knife and a few

other objects in the grave, which is customary for a rather poor low class burial (Stadler pers. comm.).

In contrast, the man from grave 334 has a precious belt and grave goods typical of upper class burials. He was buried in a proper position. All three had their heads in correct anatomical position. Generally, decapitated individuals from the late Roman-British period have their heads displaced, and sometimes the head is missing (7).

Several motives of beheading are discussed in connection with decapitated individuals in archaeological sites (6, 9, 7). Trying to understand the technique used helps us to interpret the possible social reasons motivating decapitation, and *vice versa*.

In modern practice and way of thinking, decapitation is manifested as a corporal punishment or execution. With beheading as a means of execution, traumatic lesions affecting the posterior aspects of the vertebrae with chop marks delivered from the posterior would be expected (6, 27). But even within executions two different techniques are used – by the sword and by the axe. In all modern beheadings the sword is used. Where a person is to be decapitated with a sword, a block cannot be used and people are generally forced to kneel down. In Germany women were sometimes allowed to sit in a chair. In Saudi Arabia a traditional Arab scimitar (a sword, 1000–1100 mm long) is used.

In earlier years, when the axe was the chosen implement, a wooden block, often shaped to accept the neck, was required. The prisoners knelt in front of it and had to lean forward, the neck resting on the top of the block (10).

Case two (Ind. 334) and Case three (Ind. 485) with horizontal cuts from behind allow us to assume that the decapitations were done with an axe, using a block to perform a single, powerful stroke for severing the skulls.

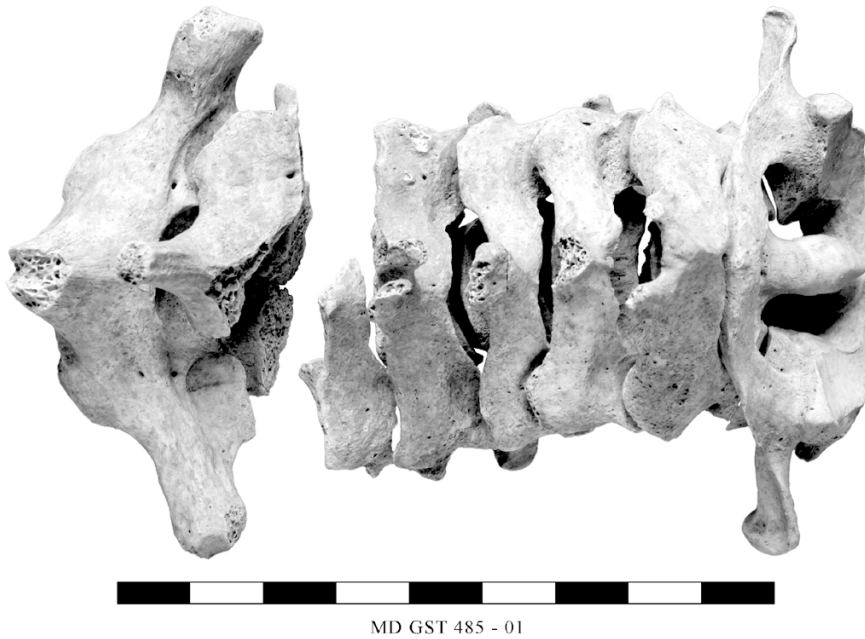

Fig. 7. The assembled vertebral column from dorsal showing a slightly angled cut through C6 and C7 (Ind. 485)

But even if the technique is identified, we cannot verify whether the Avar decapitations are a way of executing a punishment or a ritual. The two individuals from Mödling are buried regularly within the graveyard, with their head in anatomical position (Figs. 8, 9). (This can also be seen in modern beheadings in Saudi Arabia, where the decapitated head is sewn to the body again before burial (10)).

An armed confrontation is another possibility for decapitation. But in this case more than one lesion would be expected, as would occur during a fight, where

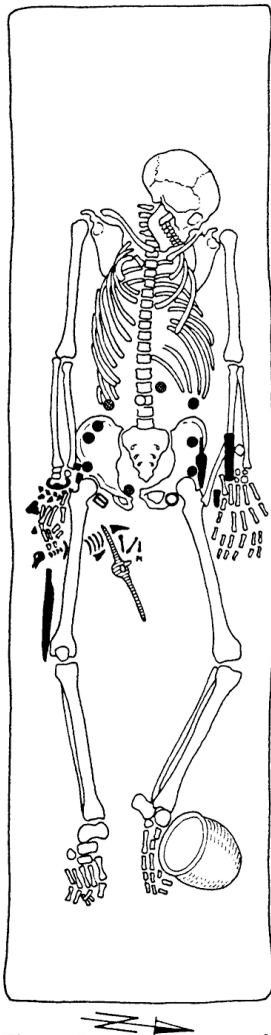


Fig. 8. Documentation of grave 334 Mödling – Goldene Stiege

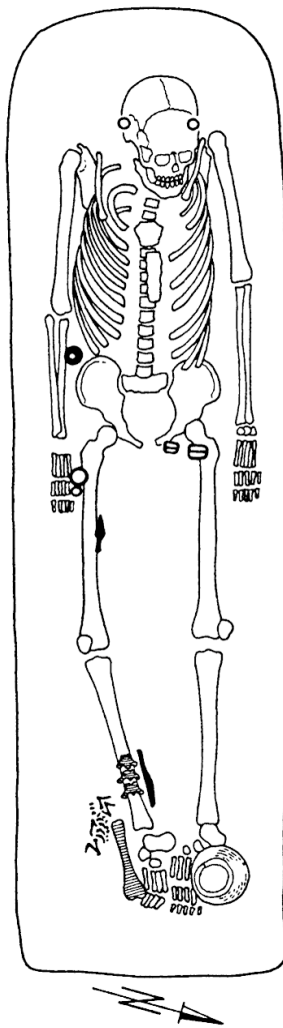


Fig. 9. Documentation of grave 485 Mödling – Goldene Stiege

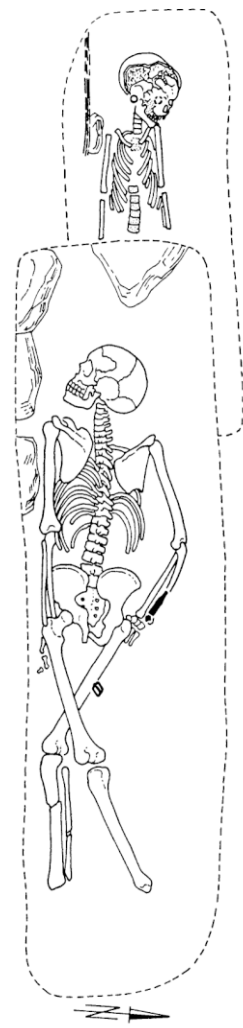


Fig. 10. Documentation of grave 203 Mödling – Goldene Stiege

generally more than one attack is carried out and different cut marks could be seen on the bones. Beheading as a final act of a fight shows an irregular form of decapitation, often with the skull base and the lower jaw involved. If these battle victims are buried, they are rarely found within urban cemeteries.

As multiple cuts to the body and the head are not seen in the presented cases, the motives for beheading as a result of an armed confrontation might be excluded.

Solely Case one (Ind. 203), incomplete decapitation with a prone burial situation, could be interpreted as a victim of an attack in an armed confrontation. At least two cuts can be seen in the region of the neck and they are rather irregular. As they do not completely sever the head, a small weapon such as a knife was probably used. The individual might have been a victim of stabbing. But it is impossible to say if the stabbing was carried out as a punishment or as murder. As the dead corpse got a very uncommonly prone burial position (Fig. 10), an irregular treatment of the dead person is obvious. Maybe being buried in a prone position was discriminating and therefore a kind of *post mortem* punishment (17).

A. Boylston (6) lists additional social reasons as motives for beheading a person, partly taken from ethnographic literature, like blood letting, trophy or relic collection, and decapitation as the result of a mismanaged hanging. These motives may be dismissed for the presented cases as the heads are present, which is atypical for trophy or relic collection. The cut marks on the vertebrae are deep and not close to the channels of the blood vessels, therefore decapitation for blood letting seems unlikely as well. Due to the fact that the dens axis is not broken and the individuals were not tied in their graves, the above-mentioned motivations of a mismanaged hanging may be ruled out too.

Another motive for beheading a person could be a sacrifice. A fact against an interpretation of a sacrifice, maybe with religious background, is the position of the graves. Two beheaded individuals with a regular burial among the whole group of 540 burials do not allow for a sufficient argument for sacrifice where one would expect a special treatment or special location connected with some possibly religious meaning. However, all sort of spirits, beliefs or interferences of *post mortem* life are difficult to reconstruct but have to be taken into account.

The three male individuals with different cut marks on their cervical vertebrae allow us to speculate about different stories of their death.

Case two, individual 334, who was an honoured person of high status, and Case three, individual 485, the “poor” person, were decapitated professionally, most probably with the head fixed on a block,

by a blow of an axe. They were buried properly with all their treasures. Maybe the first was a local leader and the other a servant executed by an opponent and put to grave with honour by his own people. But it is also possible that these individuals were punished, though with honour, by their own people and got a regular burial with the traditional burial rites.

The different cut marks on four cervical vertebrae from the left side and the unusual burial position of the male individual 203, Case one, allow us to assume another story. The individual was possibly stabbed twice with a knife from the front, maybe in an armed confrontation. He got an unusually prone burial position which was probably discriminating – and an additional way of *post mortem* punishment.

CONCLUSION

To our point of view, the three male individuals from the Avar period (630–800 A.D.) cemetery from Mödling Goldene Stiege with cut marks on their cervical vertebrae were beheaded out of different motives. Decapitation does not seem to be a frequently used rite within the Avar period people of Austria.

ACKNOWLEDGEMENTS

Many thanks to G. Bernhofer and S. Navratil for helping with the skeletal catalogue, A. M. Höger for helping with the palaeopathological descriptions and interpretations, and to B. Tobias and T. Distelberger for archaeological discussions.

Received 5 November 2004
Accepted 17 December 2004

References

- Schmidt RR. Die Altsteinzeitlichen Schädelgräber der Ofnet und der Bestattungsritus der Diluvialzeit. Stuttgart: E. Schweizerbart 1913.
- Vallois H. Les Hommes Fossiles. Paris: Masson et C^{ie}. 1946: 369–371.
- Fraye DW. Ofnet: Evidence for a Mesolithic massacre. In: Martin DL, Frayer DW, eds. Troubled Times Violence and Warfare in the Past. War and Society. Vol. 3, Gordon and Breach Publishers. 1997: 181–216.
- Neugebauer-Maresch C, Neugebauer JW. Falkenstein. Fundberichte Österreichs 36, 1997: 14.
- Wilschke-Schrotta K, Teschler-Nicola M. Die frühbronzezeitlichen Skelette aus den Speichergruben bei der Burg Falkenstein; Niederösterreich. 2005: Work in Progress.
- Boylston A, Knüsel CJ, Roberts CA, Dawson M. Investigation of a Romano-British rural ritual in Bedford, England. J Archaeol Sci 2000; 27: 241–54.

7. Philpott R. Burial Practice in Roman Britain. (B.A.R. 219) British series Sign R 8462 GB, 1991: 71–89.
8. Anderson T. Two decapitations from Roman Towcester. *Int J Osteoarchaeol* 2001; 11(6): 400–5.
9. Harmann M, Molleson TI, Price JL. Burials, bodies, and beheadings in Romano-British and Anglo-Saxon cemeteries. *Bull Br Mus nat Hist (Geol)* 1981; 35(3): 145–88.
10. Clark R. Behaeding [Online]. [cited Oct 2004] Available from: <http://www.richard.clark32.btinternet.co.uk/behead.html>
11. Szilvassy J. Die Skelette aus dem awarischen Gräberfeld von Zwölfaxing in Niederösterreich. *Anthropologische Forschungen Heft 3, Anthropologische Gesellschaft in Wien*, 1980.
12. Grefen-Peters S. Das awarische Gräberfeld von Leobersdorf, NÖ. In Daim F. eds. *Das awarische Gräberfeld von Leobersdorf, NÖ. Studien zur Archäologie der Awaren 3. (Veröffentlichungen der Kommission für Frühmittelalterforschung Nr. 10 = Denkschriften, phil.-hist. Klasse 194. Band) Verlag der Österr. Akad. d. Wissenschaften, Wien 1987: 83–324.*
13. Großschmidt K. Paläopathologische Untersuchungen an den menschlichen Skeletten des awarenzeitlichen Gräberfeldes Csokorgasse in Wien-Simmering. *Diss. Univ. Wien, Formal- u. Naturwiss. Fakultät*, 1990.
14. Berner M, Kritscher H, Szilvassy J. Die Skelette des awarischen Gräberfeldes von Münchendorf, Niederösterreich. *Archaeologia Austriaca – Monographien 1. Studien zur Archäologie der Awaren 4, Band 2, Hrsg. Daim F, 1992: 1025–191.*
15. Wiltchke-Schrotta K. Anthropologische Untersuchungen der awarenzeitlichen Skelette aus Zwölfaxing II, In Müller S. *Das awarenzeitliche Gräberfeld aus Zwölfaxing, NÖ, (ungedruckte Diplomarbeit, Wien 2004).*
16. Pany D. Die anthropologische Auswertung der awarenzeitlichen Skelette von Vösendorf, B301. *Work in progress*, 2005.
17. Fettich N. Das awarenzeitliche Gräberfeld von Pilismarót-Basaharc. *Academiae scientiarum Hungaricae Studia Archaeologica III. Budapest 1965.*
18. Anonymus. BEHEADING [Online]. *LoveToKnow 1911 Online Encyclopedia*. © 2003, 2004 LoveToKnow [cited Oct 2004] Available from: <http://2.1911encyclopedia.org/B/BE/BEHEADING.htm>.
19. Daniel S. Enthauptung funktioniert. *Profil* 34 Vienna, 16. August 2004: 68–70.
20. Wiltchke-Schrotta K. Die awarenzeitlichen Skelette von Mödling Goldene Stiege. *Work in progress*, 2005.
21. Ferembach D, Schwidetzky I, Stloukal M. Empfehlungen für die Alters- und Geschlechtsdiagnose am Skelett. *Homo* 1979; 30: 1–32.
22. Szilvassy J. Altersdiagnose am Skelett. In: R. Knußmann, (Hrsg.) *Anthropologie – Handbuch der vergleichenden Biologie des Menschen. Band I, 1, 1988: 421–43.*
23. Ubelaker D. *Human Skeletal Remains. Excavation, Analysis, Interpretation, Chicago 1978.*
24. Stloukal M, Hanáková H. Die Länge der Längsknochen altslawischer Bevölkerungen unter besonderer Berücksichtigung von Wachstumsfragen, *Homo* 1978; 29: 53–69.
25. Sjøvold T. Estimation of stature from long bones utilizing the line of organic correlation. *Hum Evol* 1990; 5(5): 431–47.
26. Schultz M. Paläopathologische Diagnostik. In: Knußmann, R., (Hrsg.) *Anthropologie Handbuch der vergleichenden Biologie des Menschen. Band I, 1, 1988: 480–95.*
27. Bennike P. *Palaeopathology of Danish Skeletons: A Comparative Study of Demography, Disease and Injury. Copenhagen: Akademisk Forlag 1985, ref. in Boylsten et. al. 2000.*

K. Wiltchke-Schrotta, P. Stadler

DEKAPITACIJA AVARØ LAIKOTARPIU (630–800 M.)

Santrauka

Tiriant žmonius palaikus neretai iškyla mirties priežasties klausimas. Deja, dažniausiai to nustatyti nebeįmanoma. Tačiau tiriant Avarø laikotarpio (630–800 m.) gyventojø palaikus iš Mödling Goldene Stiege (Austrija) tarp 540 palaidojimų rasti trys individai su pjūviø aštriais žankiais pėdsakais ant kaklo slanksteliø. Šio tyrimo tikslas buvo išnagrinėti galimybę, kad žiems asmenims buvo nukirstos galvos. Straipsnyje aprašomas pjūviø pobūdis ir reikšmė, kapinyne rasti archeologiniai radiniai – žankiai ir ginklai, taip pat aptariama šio individø socialinė padėtis. Tyrimø duomenimis, du individai iš trijų buvo nukirsdinti aprastiniu būdu, t. y. smogiant iš nugaros, tikriausiai kirviu, fiksavus galvą ant trinkos. Trečiajam galėjo būti smogta mažesniu žankiu, panašiu á peilą visiškai neatskiriant galvos. Vienas vyriškis turėjo aukštą statusą, kiti buvo neturtingi, palaidoti su skurdžiomis ákapėmis. Nudurtas asmuo, palaidotas tik su peiliu, kapo duobėje rastas kniūbsėias. Daroma išvada, kad skirtingi pjūviai ant kaklo slanksteliø ir socialiniai šio trijų vyrø skirtumai liudija, kad dekapitacija (beje, ji nebuvo dažna tarp Avarø laikotarpio Austrijos gyventojø) buvo atlikta dėl skirtingø motyvø.