

Case Report

Lower lid retraction surgical treatment

Raimonda Piðkinienė

*Eye Clinic,
Kaunas University of Medicine,
Eiveniø 2, Kaunas, Lithuania,
E-mail: irpec@yahoo.com*

The purpose of our work was to present a case report of lower lid retraction after squint surgery and the result of lid retraction surgical treatment. The normal vertical width of palpebral fissure is about 9–11 mm. The Upper and lower lid can be retracted due to different reasons, and this distance becomes larger. During our operation the lower lid retractors were lengthened by interposing a spacer of donor sclera between the cut lid retractors and the lower border of the tarsus. The final results were a symmetry of palpebral vertical fissure of both eyes and a cosmetically acceptable appearance of the patient.

Key words: lid retraction, retractor lengthening, spacer, inferior rectus recession

INTRODUCTION

Lid retraction is one of the numerous conditions that disturb the normal appearance of a patient. We present a clinical case of lower lid retraction after squint surgery and a result of plastic surgery – lower lid retractor lengthening procedure.

With the eye in the primary position the upper lid normally crosses the cornea 1.5 to 2.0 mm below the superior limbus and the lower lid reaches the inferior limbus of the cornea. So, the normal vertical width of palpebral fissure (the distance between the upper and lower lids) is about 9–11 mm (1, 3) (Fig. 1).

Due to different reasons the upper and lower lids can be retracted and this distance becomes larger. Lid retraction is a disorder of eyelid position that can affect the upper or the lower lid, or both. The condition is characterized by the appearance of a band of white sclera between the limbus and the eyelid margin or margins when the eyes are in primary position (8).

The reasons for eyelid retraction are very different – congenital, neurological, like the 7th nerve pal-

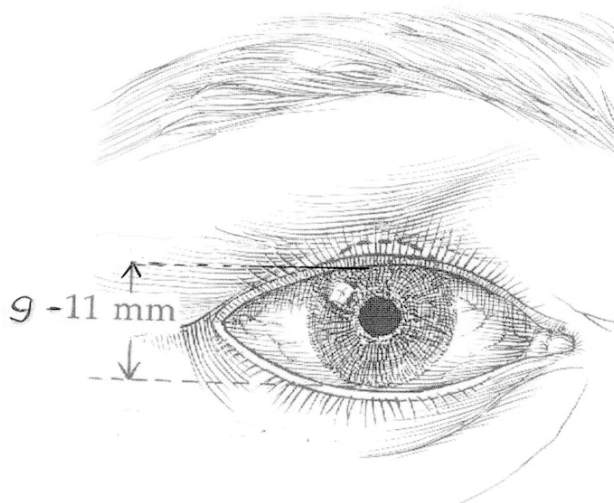


Fig. 1. Normal palpebral fissure

sy, Marcus Gunn jaw-winking syndrome, some lesions of the rostral midbrain (2, 8).

The most common etiology of eyelid retraction is thyroid ophthalmopathy, which may be present with or without exophthalmus (8). In endocrine ophthalmopathy, every forward displacement of the globe will

lead to a widening of the palpebral fissure above the normal upper value. Proptosis and retraction of the upper lid are to be ascribed to the shortening of the contractile substance of the levator palpebrae, inhibiting the orbicularis oculi, as well as an increased sympathetic stimulation of Mueller's muscle, as well as its fibrous contraction. Retraction of the lower lid also occurs because of proptosis, but is frequently amplified due to the shortening of the lid retractors (3).

The mechanical factors that cause lid retraction are trauma, scars, tissue loss, posterior or middle lid lamella shortening, complications of other surgery such as blepharoplasty, overcorrection of ptosis repair, blow-out fracture repair, large recession of the inferior rectus (2, 8).

The anatomic basis of lower lid retraction in inferior rectus recession involves anterior extensions of Tenon's capsule which surrounds the inferior rectus and the inferior oblique, thus forming Lockwood's ligament. Lockwood's ligament is the origin of the capsulopalpebral fascia, which is inserted at the lower tarsal border (8).

Excessive recession of the inferior rectus causes lower lid retraction through the check ligaments between the inferior rectus and the tarsus of the lower lid (4, 5). Retraction frequently occurs even in spite of severing the connections between the inferior rectus and the lower eyelid (6).

If lid retraction occurs despite this procedure, a recession of the lid retractors can be done (8).

MATERIALS AND METHODS

A 28-year-old female underwent strabismus surgery of the left eye. Recession of the inferior rectus was done.

We saw the patient first six months after surgery. The vertical distance between the upper and the lower eyelid was 8 mm in the right eye and 12 mm in the left eye. The distance between the inferior limbus of the cornea and the inferior eyelid was 0.5 mm in the right and 3 mm in the left eye (Fig. 2).

The patient was operated on the lower lid retractor lengthening procedure was done, interposing a graft of donor sclera between the cut lid retractors and the lower border of the tarsus (12).

RESULTS

The final results were a cosmetically acceptable appearance of the patient, a symmetry of palpebral vertical fissure in the right and left eyes, and a great satisfaction of the patient and the surgeon (Fig. 3).

DISCUSSION

Whereas the surgeon is able to apply several techniques for lowering an affected upper eyelid, correction of lower eyelid retraction does not permit such flexibility.

Freeing of the inferior eyelid retractors is anatomically equivalent to levator weakening in the upper eyelid, however, it does not elevate the lower lid because of the gravity vector with which the surgeon must contend.

Thus, a spacer is the inevitable requirement for an effective lower eyelid elevation (7). Sometimes lids receiving scleral implants become thickened and edematous postoperatively and the sclera resorbs in an unpredictable manner in many cases. Therefore, scleral grafts may end up less than cosmetically acceptable and require further surgery (9, 11). So, we demonstrate a really successful case.

Alternatively, the hammock sling procedure (10, 11) or different types of aloplastic spacers can be used.

Received 10 January 2005

Accepted 15 March 2005

References

1. Iliff CE, Iliff WJ. *Oculoplastic Surgery*. 1979: 35.
2. Collin JRO. *A Manual of Systematic Eyelid Surgery*. 2nd edition. 1989: 144.
3. Olivari N. *Endocrine Ophthalmology*. Kaden Verlag, Heidelberg, Germany 2001: 11.
4. Roth A, Speeg-Shatz. *Eye Muscle Surgery*. English edition Swets & Zeitlinger b.v., Lisse 2001: 277.
5. Huber A. Electrophysiology of the retraction syndromes. *Brit J Ophthalmol* 1974; 5: 293-300.
6. Richards R. *Strabismus Surgery*. First edition 1991, Williams & Wilkins: 143.



Fig. 2. Patient after an inferior rectus recession and before a lower lid surgery

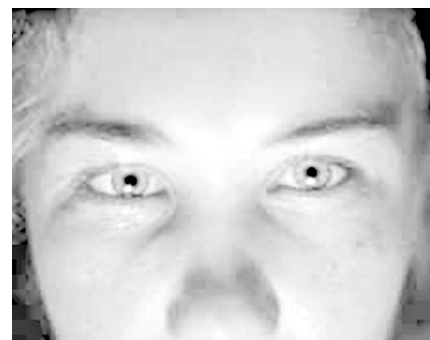

Fig. 3. The same patient after a lower lid lengthening procedure

7. Beyer-Machule ChK. Surgical treatment of thyroid-related eyelid retraction. *International Ophthalmology Clinics* 1989; 29(4): 233.
8. Heffernan JT, Tenzel RR. Lid retraction. *Current Ocular Therapy*. USA: W.B. Saunders Company 1995: 583.
9. Dryden RM, Soll DB. The use of scleral transplantation in cicatricial entropion and eyelid retraction. *Trans Am Acad Ophthalmol Otolaryngol* 1971; 83: 669.
10. Heffernan JT, Tenzel RR. Correction of vertical retraction of the lower lid with an orbicularis hammock. *Ophthalmic Plast Reconstr Surg* 1989; 5: 92–8.
11. Heffernan JT, Tenzel RR. Lid retraction current ocular therapy. USA: W.B. Saunders Company 1995: 584.
12. Collin JRO. *A manual of systematic eyelid surgery*, 2nd edition 1989: 146.
13. Olivari N. *Endocrine Ophthalmopathy*. Kaden Verlag, Heidelberg, 2001: 12.

Raimonda Piðkinienė

APATINIO VOKO RETRAKCIJOS CHIRURGINIS GYDYMAS

S a n t r a u k a

Normalus vertikalus voko plyðio matmuo yra apie 9–11 mm. Dël ávairiø prieþasèiø, sukelianèiø virðutinio ar apatinio voko retrakcijà, ðis matmuo gali padidėti. Ðiame darbe pateikiame sėkmingà apatinio voko retrakcijos, atsiradusios po apatinio tiesiojo raumens recesijos, chirurginio gydymo atvejà. Operacijos metu apatinis vokas pailgintas, tarp jo apatinio kremzlės kraðto ir voko retraktoriø ásiuvant donorinës skleros intarpà. Operacijos rezultatas: simetrija tarp abiejø akiø vokø plyðiø ir geras kosmetinis efektas.

Raktaþodþiai: vokø retrakcija, retraktoriø pailginimas, intarpas, apatinio tiesiojo raumens recesija