

# Videothoracoscopy in the diagnosis and treatment of lung and pleural diseases

**Dainius Amerigas Piðeikas,**  
**Saulius Cicėnas,**  
**Arnoldas Krasauskas**

*Vilnius University Institute of  
Oncology, Department of Thoracic  
Surgery and Oncology, Lithuania*

**Objective.** To evaluate the efficacy of videothoracoscopic operations in the diagnosis and treatment of lung and pleural diseases, complications and outcome.

**Materials and methods.** In 1997–2004, at the Department of Thoracic Surgery and Oncology of Institute of Oncology, Vilnius University, 322 operations were performed using videothoracoscopic devices of them 86 were resections: 6 (7%) lobectomies, 9 (10.5%) wedge resections of lungs tissue due to I°. NSCLC performed for the elderly, 30 (35%) metastases removal, 17 (19.8%) hamartomas, 3 (3.5%) pericardial cystectomies, 7 (8%) sympatectomies, 5 (5.8%) intrathoracal lipomectomies, 2 (2.4%) calcificate removal, 3 (3.5%) resections of pericardium. 236 diagnostic procedures were performed in patients with various lung and pleural diseases: 76 (32%) biopsies of lungs and pleural tissue and 160 (68%) biopsies with chemopneurodesis. During thoracoscopies we confirmed the diagnoses morphologically: tumour extention 41% (90 pts from 219), pleural mesothelioma 19% (42 pts), inflammation 27% (59 pts), tuberculosis 5% (11 pts), benign tumour 8% (17 pts). We performed chemopneurodesis in mesothelioma – 18 (11%) pts, malignant lesion – 69 (43%) pts, benign pleural effusion – 51 (32%) pts, TBC pleuritis – 11 (7%) pts, chylothorax – 11 (7%) pts.

**Results.** From the oncological point of view, videothoracoscopic operations are confirmed. These operations shorten hospitalisation and combined treatment starts earlier. The mean period of hospitalization is 5 days. The complication rate was 13.7%: 32 cases of (10%) postoperative pneumonia, 8 (2.5%) cases of short-lasting pneumothorax, 2 (0.6%) bleedings, 1 (0.3%) pleural empyema, 1 (0.3%) drop of the lung. We had no perioperative mortality. One patient (0.32%) died. All other patients (99%) recovered. Pneurodesis by talc insufflation (also known as talc poudrage) results in short- and long-term success (92%, 147 pts from 160). After resection, the margins were free of tumor invasion. The diagnostic efficiency of thoracoscopy was 97% (322 of 333 cases).

**Conclusions.** VATS surgery is an effective and safe diagnostic and treatment method for lung and pleural diseases. The diagnoses were confirmed in 93% of cases. Sometimes VATS surgery is the only way to remove tumours, and it shortens hospital stay to 5 days. This method should be used for elderly patients with limited pulmonary function (FEV1 < 1.0 litre, or <35% predicted; DLCO <40%, age >75 years; no endobronchial lesions) or for patients with significant co-morbid diseases. Early stage NSCLC may be effectively treated by anatomic resection with a good two year survival (83%, 5 pts from 6). The use of VATS techniques for wedge resection may be needed in highly selected patients such as those with a poor lung function and co-morbid diseases, or those with clinical T1N0 or T2N0 disease in whom a muscle sparing thoracotomy carries more risk than VATS. After this resection the two-year survival was 80% (8pts from 10). Insufflation of talc powder during thoracoscopy is the best conservative method of pleurodesis in malignant and recurrent benign effusions, including chylothorax. Success rate was 92% (147 pts from 160).

**Key words:** VATS, biopsy of lungs tissue and pleura, wedge resections, lobectomy, chemopneurodesis

## INTRODUCTION

Methods of clinical minimal invasive surgery appeared in the 20th century. H. C. Jacobsen in 1910 used a cystoscope to observe the pleural cavity (1). VATS surgery flowers in Europe after treatment of pneumothorax for TB patients, lung and pleural malignant diseases and empyema, stopping cancer spread into the pleural space (2). From 1960, due to successful conservative treatment of TB patients, VATS surgery was forgotten. Some centres in Europe used VATS for the diagnosis and treatment of pleural diseases (3). From 1990, with the introduction of fiberoptic cables in thoracic surgery, manufacturing anesthesia devices, creating new endosuture staplers, VATS surgery was renovated and many operations could be done with VATS.

Thoracoscopy is today primarily a diagnostic procedure, but it can also be applied for therapeutic purposes. Pleural effusions are by far the leading indication for medical thoracoscopy both for diagnosis, mainly in exudates of unknown etiology, for staging diffuse malignant mesothelioma or lung cancer, and for treatment by talc pleurodesis malignant or other recurrent effusions, or in cases of empyema. Spontaneous pneumothorax for staging and, in stage I and II, for local treatment is also an excellent indication. For those who are familiar with the technique, other (mainly diagnostic) indications are biopsies from the diaphragm, the lung, the mediastinum and the pericardium. In addition, medical thoracoscopy offers a remarkable tool for research as a "gold standard" in the study of pleural effusions.

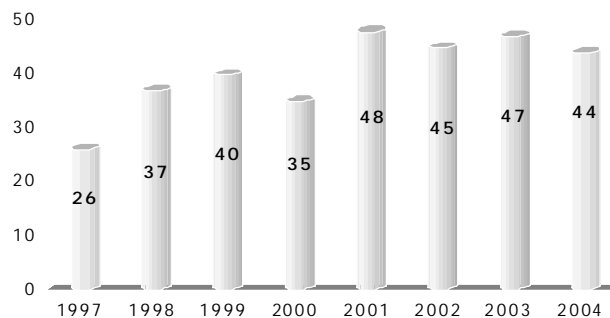
Due to technical improvements and a trend towards less invasive procedures, thoracoscopy was rediscovered by thoracic surgeons at the beginning of this decade, and named "surgical" thoracoscopy, which is more precisely known as video-assisted thoracic surgery (VATS). This revival has also supported the introduction of "medical" thoracoscopy into the scope of respiratory physicians, particularly in the USA where, according to a national survey in 1994, already more than 5% of all pulmonologists were applying medical thoracoscopy.

In 1997, VATS surgery was introduced at the Department of Thoracic Surgery of Institute of Oncology, Vilnius University. Our objective was to evaluate the efficacy of videothoroscopic operations in the diagnosis and treatment of lung and pleural diseases, complication rates, outcome.

## MATERIALS AND METHODS

In 1997–2004 at the Vilnius University Institute of Oncology we performed 322 videothoroscopies (Fig. 1).

Preoperative evaluation included chest radiography, thoracentesis (when indicated), respiratory func-



**Fig. 1.** The number of videothoroscopies performed at Vilnius University Institute of Oncology, 1997–2004

tion tests, and ECG. Flexible bronchoscopy and chest CT were performed when clinically indicated.

Thoracoscopy is usually performed through one or several small, <2-cm skin incisions made along the intercostal spaces. Patients are placed in the lateral decubitus position, involved side up, although some procedures, such as thoracic sympathectomy, are performed with patients in the supine position. Pleural trocars can also be safely placed in the axilla, so that axillary thoracoscopy can potentially precede an axillary thoracotomy. We used general anesthesia with single- or double-lumen endotracheal intubation performed in an operating suite. Many procedures limited to removal of pleural fluid, visualization, and biopsy of parietal pleura can be performed through a single skin incision made in approximately the fifth to seventh intercostal space along the lateral chest wall of the involved hemithorax. When a 5- to 10-mm pleural trocar and cannula are inserted through the incision, the parietal pleura, diaphragm, and lung are well visualized. Pleural fluid evacuated and parietal pleural biopsy specimens are obtained from both normal- and abnormal-appearing areas. A chest tube is placed through incision site and connected to a suction device, and the lung is gently reexpanded.

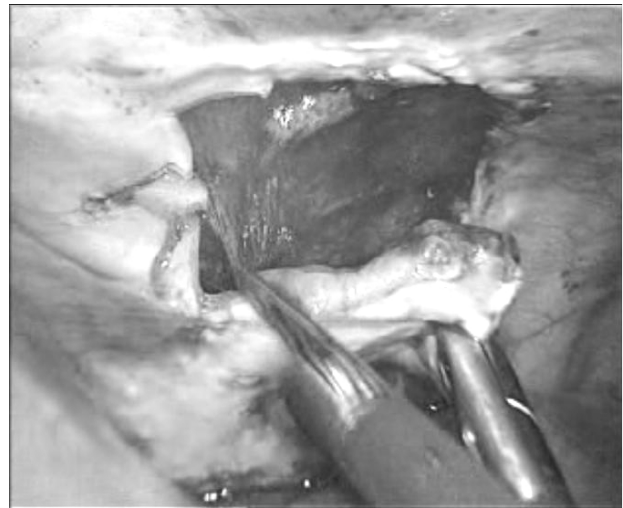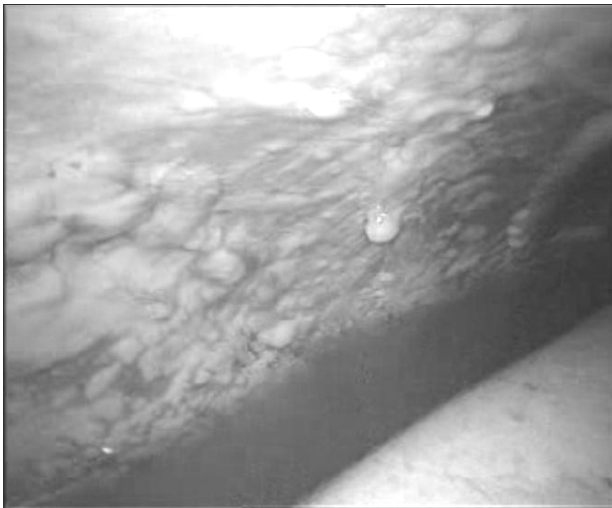The mean age of the patients was  $61 \pm 15$  years. We have performed 86 resections and 236 diagnostic procedures in patients with various lung and pleural diseases, which included 76 (32%) biopsies of pleura tissue and 160 (68%) biopsies with chemopleurodesis.

The endoscopic view of a metastatic pleural cavity and endoscopic pleural biopsy are shown in Fig. 2.

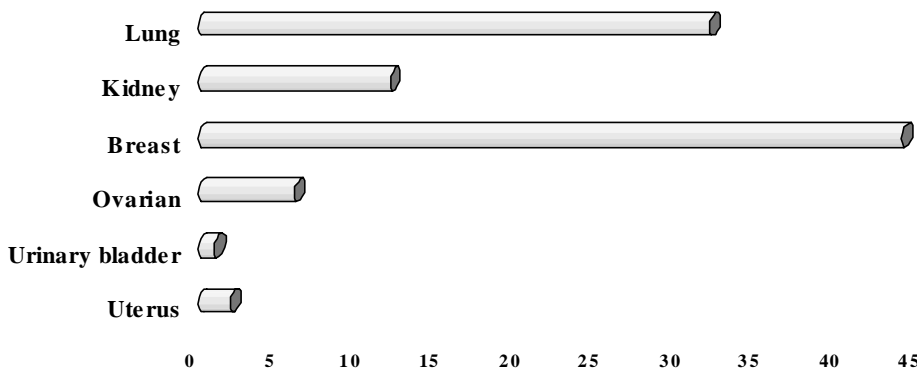
Removed pleural metastases according to primary tumour site are characterized in Fig. 3.

The technical feasibility of video-assisted lobectomy or thoracoscopic lobectomy has been aggressively assessed and confirmed in recent years. However, to adequately assess the value of this surgical technique, its feasibility also must be evaluated in more compromised patients, such as those with poor pulmonary reserve and the elderly.

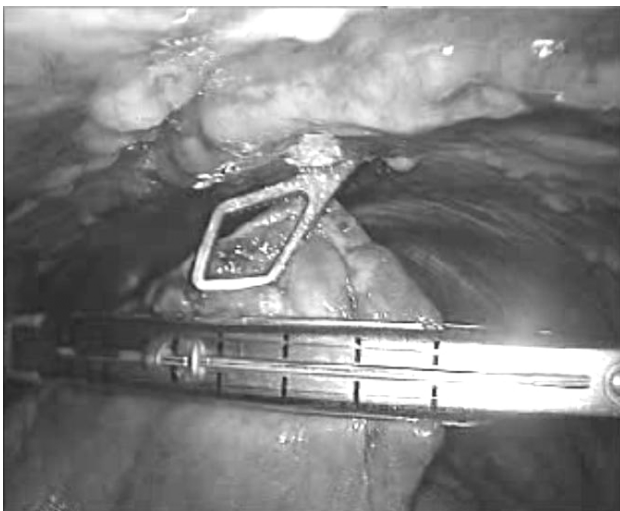For 6 (7%) pts were performed lobectomies: 2 upper and 4 lower. Four patients had IA – T1N0 squamous cell CA and two patients had IB – T2N0



**Fig. 2.** Endoscopic view of metastatic pleural cavity and endoscopic pleural biopsy



**Fig. 3.** Pleural metastases according to primary tumour



**Fig. 4.** Endoscopic view of lung metastasis removal

adenoCA. Lobectomy was performed with anatomic individual ligation and separation of pulmonary veins, arteries, interlobar fissures, and bronchus with a stapler. The procedure was performed in the following order of stapling or ligation and division of anatomic structures: for upper lobectomy (1) superior pulmonary vein; (2) superior trunk of the pulmonary artery; (3) interlobar division; and (4) upper lobe

bronchus; for lower lobectomy (1) interlobar division; (2) basal pulmonary artery (with separate ligation of A6); (3) lower lobe bronchus; (4) interlobar fissures; (5) inferior pulmonary vein; and (6) pulmonary ligament. We resected all identifiable nodes in the ipsilateral thorax for accurate pathologic staging

to ensure an appropriate postoperative therapy. The subcarinal and the tracheal bifurcation were removed to ensure an adequate resection of these nodes.

For patients with poor pulmonary reserve and the elderly we performed, 9 (10.5%) wedge resections of lung tissue to I° NSCLC (T1 adenocarcinoma and T2 squamous cell carcinoma).

The lungs are the second most frequent site of metastases and often the only location of metastatic disease. Most pulmonary metastases are located in the lung periphery and are immediately subpleural. This location makes them particularly amenable to VATS resection. We removed lung metastases for 30 (35%) pts from primary sites (2 pts had double metastases): 4 pts uterus carcinoma, 18 pts kidney carcinoma, 6 pts breast carcinoma, 2 pts lung adenocarcinoma. VATS parenchymal-sparing wedge resection was performed with an endoscopic stapler. The endoscopic view of lung metastasis removal is shown in Fig. 4.

In cases of pleural effusion, we suggest that the fluid should not be evacuated just before the operation. The patients with pleural effusion tolerated the procedure extremely well, because they were used to functioning with a partial lung collapse. We used 4–8 g sterile talc powder which was blown gradually on expanding the lung. The diseases for which we performed pleurodesis and the diagnoses during tho-

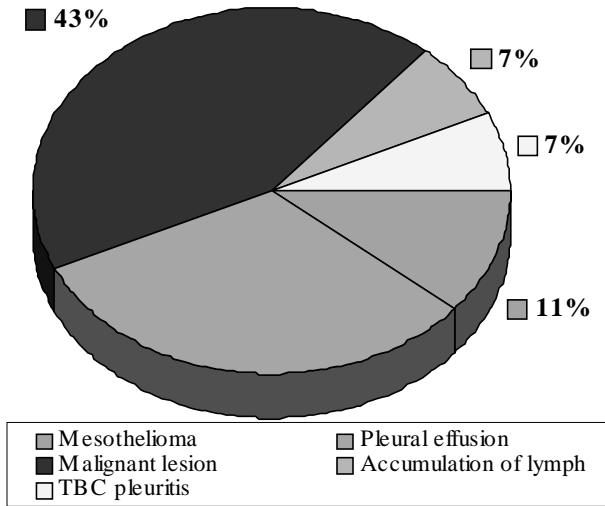


Fig. 5. Diseases for which pleurodesis was performed

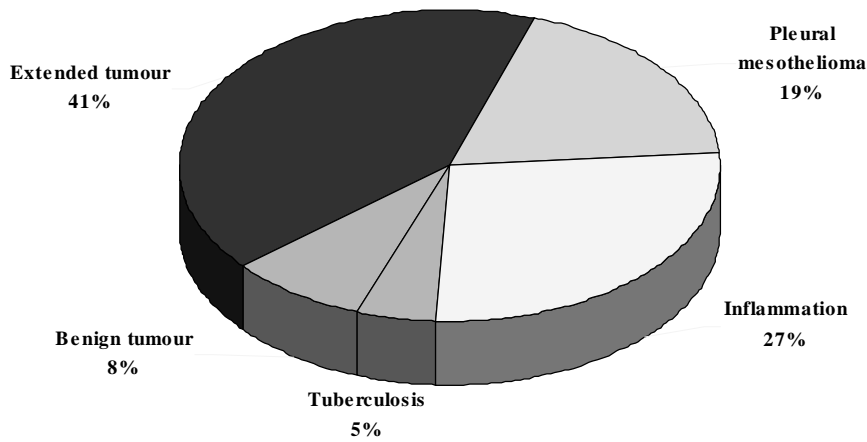


Fig. 6. Clinical diagnoses confirmed by pathologist

racoscopies confirmed morphologically are shown in Figs. 5 and 6. The endoscopic view of pleurodesis with sterile talc powder is shown in Fig. 7.

For 17 (19.8%) pts we removed hamartomas in 2 (2.4%) pts calcificate, localised in marginal lung seg-

ments with endoscopic staplers or using the endoscopic suture technique were removed (Fig. 8).

For 5 (5.8%) pts we performed intrathoracal lipomectomies. For their radiological and endoscopic view, see Fig. 9.

Seven (8%) sympatectomies were performed for patients with Raynaud disease. In 6 (86%) patients there were no recurrences. For 7 (8%) pts resections of pericardium (5 cases were malignant wet pericarditis and 2 benignum pericarditis) were performed. Three (3.5%) pericardial cystectomies were performed with electrocoagulation. All patients recovered. The endoscopic view of pericardium and pericardial cyst resection is shown in Figs. 10 and 11.

Postoperatively, a chest radiograph was obtained daily to ensure full lung expansion and to check for any pneumothorax or residual effusion. The intercostal underwater seal drainage was generally under suction for 24 to 48 h, and it was removed the day after the procedure or when the drainage was < 100 ml/d.

**RESULTS**

After lung tissue wedge resections all margins of tissue were "free" from tumours. After lobectomies, there were no metastases in removed lymph nodes (histological). In all 236 diagnostic procedures which were performed in patients with various lung and pleura diseases the diagnosis was confirmed histologically. The mean period of hospitalization after videothorascopies was 5 days (8 ± 3). Most experts agree that when the initial evaluation of a pleural effusion is nondiagnostic, especially when neoplastic disease is suspected, thorascopic explo-


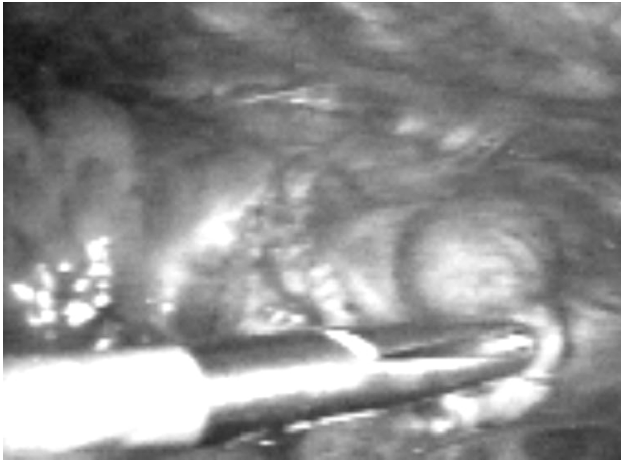
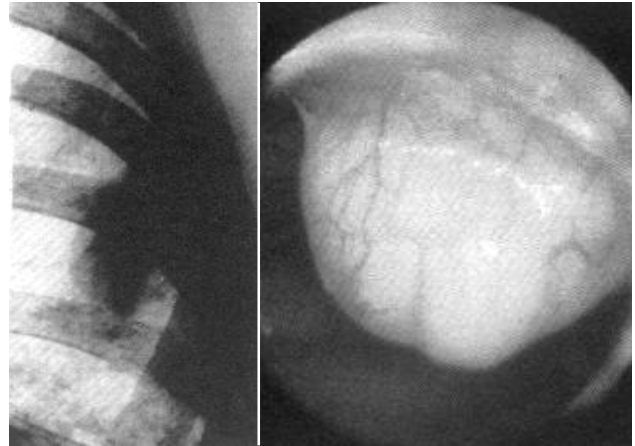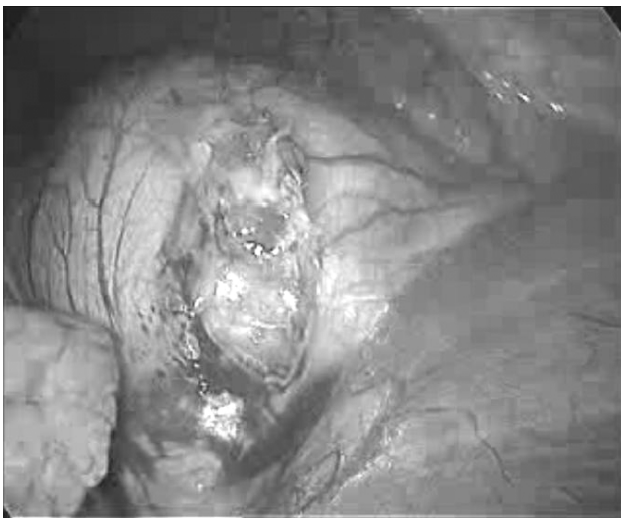


Fig. 7. Endoscopic view of pleurodesis with sterile talc powder



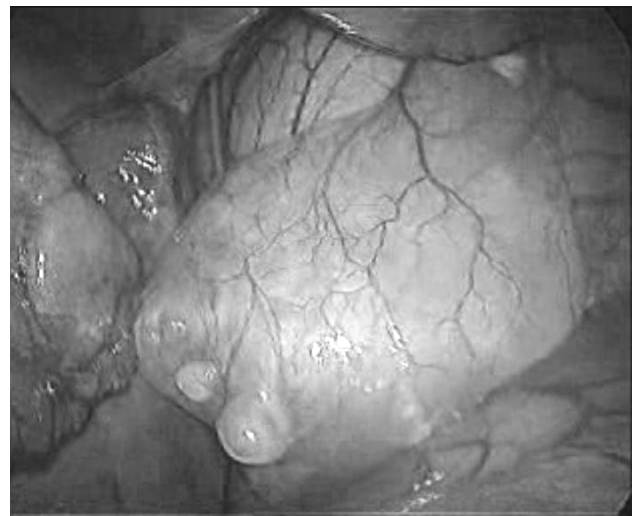**Fig. 8.** Endoscopic hamartoma removal




**Fig. 9.** Radiological and endoscopic view of intrathoracic lipoma



**Fig. 10.** Endoscopic view of pericardium resection



**Fig. 11.** View of pericardial cyst




**Fig. 12.** The value of diagnostic methods

ration and parietal pleural biopsy should be considered. The diagnostic accuracy of thoracoscopy is between 90 and 100%, compared with an approximate sensitivity of 44% for closer needle pleural biopsy and 62% for fluid cytology; false negatives occur most frequently in cases of early malignant mesothelioma. If the patient has a malignancy and negative cytology on thoracocentesis, thoracoscopy is preferred over closer needle pleural biopsy, because it will establish the diagnosis in >93% (219

pts from 236) of cases. The value of diagnostic methods is shown in Fig. 12.

In addition to diagnosis, an important indication for thoracoscopy in patients with malignant pleural effusions is pleurodesis. Complete evacuation of pleural fluid, maximization of lung expandability by removing adhesions, and pleurodesis by talc insufflation (also known as talc poudrage) result in short- and long-term success (92%, 147 pts from 160). After one year no pleural effusions were observed. The distribution of sterile, asbestos-free talc powder on all pleural surfaces is confirmed by thoracoscopic visualization. Following pleurodesis, low-grade fevers should be expected in up to 30% of patients, and hospitalization duration averages to 4.8 days. Pleurodesis can also be achieved by pleurectomy using a



**Fig. 13.** Complication rate after VATS

standard dissection technique or hydrodissection. For recurrent pleural effusions of benign etiology, the results are usually excellent when talc is used, with success rates varying from 65 to >90%.

The diagnostic efficiency of thoracoscopy was 97% (322 of 333 cases). In five cases thoracoscopy was followed by thoracotomy because of extensive adhesions between the two pleural leaves. In six cases there was bleeding.

The complication rate was 13.7% (Fig. 13). We had the following complications: 32 (10%) patients developed postoperative basal pneumonia (due to a low patients activity), 8 (2.5%) patients had a short lasting pneumothorax (due to air leakage through mechanical sutures), because emphysematous changes in the lung parenchyma in elderly patients can make mechanical stapling difficult and prolong postoperative air leakage. Two (0.6%) patients showed bleeding, 1 (0.3%) patient had pleural empyema and 1 (0.3%) drop of the lung.

We had no perioperative mortality in our series of 322 videothoroscopic operations. One patient (0.32%) died on the 21st postoperative day because of empyema and later contralateral pneumonia. All other patients (>99%) recovered.

## DISCUSSION

Many literature sources mention that radiological diagnostics is not informative enough (4). The main method of diagnostics is still lung and pleural biopsy and morphological diagnosis confirmation (5). Using VATS, we could easily diagnose different pleural and lung diseases. J. Ginsberg, M. Goldberg in 1989 wrote about VATS treatment of lung and pleural diseases. They indicated that this is a reliable and safe method of diagnostics and treatment: with a 89% sensitivity and 100% indicated morphological diagnosis. Authors under live safety of VATS and complications rate were 5–10% of all cases (6). This method should be used for elderly patients with limited pulmonary function (FEV1 < 1.0 litre, or <35% predicted; DLCO <40%, age >75 years; no endobronchial lesions) or in patients with a significant co-morbid disease (7, 8). Our results show that in 322 VATS surgery cases, the complication rate was 13%, the diagnosis was confirmed in 93% of cases. VATS surgery found its place in treatment and diagnosis of pleural and lung diseases. VATS wedge resection for treatment of non-small cell lung carcinoma (NSCLC), while not

specifically contraindicated, must be justified for the individual patient and may be contraindicated in the psychologically fit individual. Segmentectomy or wedge resection have been proposed for NSCLC. In our cases, the two-year survival

after anatomic resection was 83% (5 pts from 6), and after wedge resection 80% (8 pts from 10). The Lung Cancer Study Group conducted a prospective multi-institutional trial comparing limited resection with lobectomy for patients with peripheral T1N0 NSCLC (9). Both surgical techniques were performed open, under direct vision. In limited resection patients, recurrence rates were increased, with local recurrence rates triple that of the lobectomy group, and a worse survival: a 30% increase in overall death rate and 50% in death with cancer. Limited pulmonary resection for NSCLC did not improve morbidity, mortality, or postoperative functions. With high local / regional recurrence rates and the higher death rates with limited resection, lobectomy must be considered the standard approach for patients with peripheral T1N0 NSCLC. Therefore, the standard operative approach for patients with a T1 or T2 NSCLC remains thoracotomy, anatomic resection, and mediastinal lymph node staging / dissection. The incision, whether open (standard) or closed, should not compromise the surgeon's ability to perform the needed operation completely and safely (10). Over the past 20 years, minimally invasive surgery techniques have been applied for the diagnosis, staging, and treatment of thoracic diseases (11, 12).

In metastatic pleural effusions, biopsies of the visceral and diaphragmatic pleura are only possible under direct vision. Since the chest wall pleura is frequently (approximately in 30% of cases) not involved, it is impossible in these cases to provide a diagnosis by blind needle biopsy (13). Furthermore, because of the large size of biopsies obtained at thoracoscopy it may be much easier for the pathologist to suggest the organ from which the tumour originates (14). In metastatic breast cancer, tissue can be obtained for determination of hormone receptors (15). Even with lymphomas, the diagnostic yield as well as the morphological classification is improved. (16).

Therapeutically, several litres of fluid can be completely and immediately removed during thoracoscopy with little risk of pulmonary oedema, because of immediate equilibration of pressures by direct entrance of air into the pleural space (17). Furthermore, the re-expansion potential of the lung can be evaluated by visual inspection. In addition, the extent of intrapleural tumour spread can be described using a scoring system which correlates quite close with survival (18). The main advantage is certainly

that talc poudrage can be performed during medical thoracoscopy, which today is the best conservative option for pleurodesis (19, 20), possibly because a very even distribution of the talc powder to all parts of the pleura is achieved. It has also been shown to be very efficient in the treatment of lymphomatous chylothorax (21).

## CONCLUSIONS

1. VATS surgery is an effective and safe method of diagnostics and treatment for lung and pleural diseases. The diagnoses were proved in 93% of cases.

2. Sometimes VATS surgery is the only way to remove tumours, and it shortens hospital stay till 5 days. This method should be used for elderly patients with a limited pulmonary function ( $FEV_1 < 1.0$  litre, or  $< 35\%$  predicted;  $DLCO < 40\%$ , age  $> 75$  years; no endobronchial lesions) or patients with significant co-morbid diseases.

3. Early stage NSCLC may be effectively treated by anatomic resection with a good two-year survival (83%, or 5 from 6 patients).

4. The use of VATS techniques for wedge resection may be needed in highly selected patients such as those with a poor physiological status (poor lung function, co-morbid diseases) or those with clinical T1N0 or T2N0 disease in whom a muscle sparing thoracotomy carries more risk than VATS. After this resections, the two-year survival was 80% (8 pts from 10).

5. The insufflation of talc powder during thoracoscopy is the best conservative method of pleurodesis in malignant and recurrent benign effusions, including chylothorax. The success rate was 92% (in 147 pts from 160).

Received 16 June 2005

Accepted 18 October 2005

## References

- Jacobaeus HC. Über die Möglichkeit der Zystoskopischen Untersuchung Serosser Hohlräume anzuwenden. München Med Wochenschr 1910; 40: 2090.
- Coba F. Atlas Thoracoscopicon. Heidelberg: Mailand, Springer and Kupfer, 1928.
- Boutin C, Viallat JR, Cargnini P, Fariße P. Thoracoscopy and malignant pleural effusions. Am Rev Respir Dis 1981; 124: 588–92.
- Shields TW ed. General Thoracic Surgery. Baltimore: Williams & Wilkins, 1994.
- Hazelrigg SR, Nunchshuk SK, Cicero J. Video-assisted Thoracic Surgery Study Group, Video-assisted thoracic surgery study data. Ann Thorac Surg 1993; 56: 1039–44.
- Ginsberg RJ, Rice TW, Goldber M, Waters PF. Extended cervical mediastinoscopy and VATS: a single staging procedure for bronchogenic carcinoma of the left upper lobe. J Thorac Cardiovasc Surg 1987; 94: 673–6.
- Miller JI, Jr. VATS method in elderly patients. Ann Thorac Surg 1993; 56: 769–71.
- Shennib HA et al. Videothoracoscopy possibilities for patients with limited pulmonary function. Ann Surg 1993; 218: 555–60.
- Ginsberg RJ et al. (Lung Cancer Study Group). A prospective multi-institutional trial. Ann Thorac Surg 1995; 60: 615–23.
- Yim AP et al. Videothoracoscopy or the standart operative approach for the patient with a T1 or T2 NSCLC. Chest 1996; 109: 13–7.
- Naruke T et al. VATS and treatment of thoracic diseases. Ann Thorac Surg 1993; 56: 661–3.
- Hau T et al. Minimally invasive surgery techniques for the diagnosis and staging. Eur J Surg 1996; 162: 23–8.
- Canto A, Rivas J, Saumench J, Morera R, Moya J. Points to consider when choosing a biopsy method in cases of pleurisy of unknown origin. Chest 1983; 84: 176–9.
- Boutin C, Viallat JR, Cargnino P, Fariße P. Thoracoscopy in malignant pleural effusions. Am Rev Respir Dis 1981; 124: 588–92.
- Levine MN, Young JE, Ryan ED, Newhouse MT. Pleural effusion in breast cancer. Thoracoscopy for hormone receptor determination. Cancer 1986; 57: 324–7.
- Celikoglu F, Teirstein AS, Krellenstein DJ, Strauchen JA. Pleural effusion in non-Hodgkin's lymphoma. Chest 1992; 101: 1357–60.
- Brandth HJ, Loddenkemper R, Mai J. Atlas of Diagnostic Thoracoscopy. New York, Thieme Stuttgart, Thieme Inc., 1985.
- Sanchez-Armengol A, Rodriguez-Panadero F. Survival and talc pleurodesis in metastatic pleural carcinoma, revisited. Report of 125 cases. Chest 1993; 104:1482–5.
- Kennedy L, Sahn SA. Talc pleurodesis for the treatment of pneumothorax and pleural effusion. Chest 1994; 106: 1215–22.
- Rodriguez-Panadero F, Antony VB. Pleurodesis. State of the art. Eur Pespri J 1997; 10: 1648–54.
- Mares CC, Mathur PN. Thoracoscopic tale pleurodesis for lymphoma induced chylothorax, a case series of twenty two treated hemithoraces in eighteen patients. Am J Respir Crit Care Med 1997; 155: A481.

**Dainius Amerigas Piðeikas, Saulius Cicenas,  
Arnoldas Krasauskas**

## VAIZDO TORAKOSKOPIJOS GALIMYBËS DIAGNOZUOJANT BEI GYDANT PLAUËIØ IR PLEUROS LIGAS

S a n t r a u k a

**Tikslas.** Ávertinti vaizdo torakoskopiniø operacijø galimybes nustatant ir gydant plauëiø, pleuros ligas ir komplikacijas.

**Medþiaga ir metodai.** 1997–2004 m. Vilniaus universiteto Onkologijos instituto Torakalinës chirurgijos ir onkologi-

jos skyriuje naudojant vaizdo torakoskopà atliktos 322 operacijos. Ið jø 86 rezekcijos: 6 (7%) lobektomijos, 9 (10,5%) kylinës plauëio rezekcijos dël pirmos stadijos NSLPV senyvo amþiaus ligoniams, 30 (35%) ligoniø paðalintos metastazës, 17 (19,8%) paðalintos hamartomos, 3 (3,5%) – perikardo cistos, 7 (8%) – simpatektomijos, 7 (8%) – pleuros ertmës lipomos, 2 (2,4%) paðalinti kalcifikatai, 3 (3,5%) – perikardo rezekcijos. Atliktos 236 diagnostinës procedûros ligoniams, sergantiems ávairiomis plauëio ir pleuros ligomis: 76 (32%) – plauëio ir pleuros audiniø biopsijos ir 160 (68%) – biopsijos su pleurodeze. Vaizdo torakoskopiniu bûdu morfologiðkai patvirtinome ðias ligas: iðplitæs navikinis procesas – 41% (90 ið 219), pleuros mezotelioma – 19% (42), uþdegiminës ligos – 27% (59), tuberkuliozë – 5% (11), nepiktybiniai augliai – 8% (17). Buvo atliktos pleurodezës ligoniams, sergantiems: mezotelioma – 18 (11%), piktybiniu pleuritu – 69 (43%), áprastu pleuritu – 51 (32%), TBC pleuritu – 11 (7%), dël limfos kaupimosi – 11 (7%).

**Rezultatai.** Onkologiniu poþiûriu vaizdo torakoskopinës operacijos yra tikslingos, nes trumpina hospitalizacijos laikà ir leidþia greièiau pradëti kombinuotà gydymà. Vidutinis hospitalizacijos laikas – 5 dienos. Komplikacijø daþnis – 13,7%. Stebëjome ðias komplikacijas: 32 (10%) pooperacinës pneumonijos, 8 (2,5%) trumpalaikiai oro prasiverþimai pro mechanines siûles, 2 (0,6%) kraujavimai, 1 (0,3%) þulingas pleuros uþdegimas, 1 (0,3%) plauëio kolapsas. Mirties

atvejø operacinëje nebuvo. 99% ligoniø pasveiko. Vienas ligonis (0,32%) mirë 21 parà po operacijos. Pleurodezës, ápuëiant talkà, efektyvumas – 92% (147 ligoniams ið 160 skystis pleuros ertmëje nebesikaupë). Po kyliniø plauëio audinio rezekcijø kraðtuose navikiniø lãsteliø histologiðkai nerasta. Vaizdo torakoskopijos efektyvumas – 97% (322 atvejai ið 333).

**Iðvados.** 1. Vaizdo torakoskopinës operacijos yra efektyvios ir saugios diagnozuojant bei gydant plauëio ir pleuros ligas. Diagnostikà nustatyta 93% ligoniø. 2. Kai kuriais atvejais tai yra vienintelis bûdas paðalinti auglá ir sutrumpinti hospitalizacijos laikà iki 5 dienø. Ðis bûdas taikomas senyvo amþiaus ligoniams esant kvëpavimo nepakankamumui ar sergant gretutinëmis sunkiomis ligomis. 3. Ankstyvos NSLPV stadijos gali bûti efektyviai gydomos atliekant anatomines rezekcijas; geri dvejø metø iðgyvenimo rezultatai 83% (5 ligoniai ið 6). 4. Vaizdo torakoskopinë plauëio audinio kylinë rezekcija gali bûti atliekama ir pasiteisina blogos fiziologinës bûklës ligoniams ar kliniðkai sergantiems vëþiu su T1N0 ar T2N0 iðplitimu, kuriems negalima atlikti tipinës torakotomijos. Po ðiø rezekcijø dvejø metø iðgyvenimas – 80% (8 ligoniai ið 10). 5. Talko milteliø ápûtimas torakoskopijos metu yra geriausias pleurodezës konservatyvaus gydymo bûdas sergant piktybiniais ir uþsitæsusiais gerybiniais ðlapiais pleuritais ar esant limfos kaupimuisi pleuros ertmëje. 92% (147 ligoniams ið 160) po ðiø operacijø skystis daugiau nebesikaupë.