

Case reports

Has ROP antenatal risk factors?

Rasa Sirtautienė¹,

Rasa Bagdonienė¹,

Bronius Jurevičius²

¹ Vilnius University Children's Hospital, Vilnius, Lithuania

² National Centre of Pathology, Vilnius, Lithuania

Background: Retinopathy of prematurity (ROP) is a disease affecting the formation of retinal blood vessels in the premature infant's retina. Retinopathy of prematurity occurs when there is the cessation of normal retinal vascularization. Aim of the study – to review the development of the retina and its vasculature and to present unusual case of retinopathy of prematurity like changes found 26 hours after the birth of premature infant.

Materials and methods: Fourteen eyes of the seven autopsied fetuses and infants born during 17–36 gestational weeks were investigated.

Results: Histological pictures of the peripheral retina are presented. In 6 cases histology of the retina was similar as described in the literature and corresponded to normal retinal development. In one case (2 eyes) changes of retina were identified 26 hours after the premature birth. The findings correspond to the changes characteristic to the stage I ROP

Conclusions: Understanding of the retinal development and angiogenesis is necessary to appreciate the earlier stages of the retinopathy of prematurity. We speculate that the development of ROP is determined not only by postnatal but also by certain antenatal factors.

Key words: retinopathy of prematurity, histopathology

INTRODUCTION

Retinopathy of prematurity (ROP) is a disease affecting the formation of retinal blood vessels in the premature infant's retina. In normal retina development, the retina begins to be vascularized in the second trimester of gestation. This vascularization of the retina occurs in concert with the normal differentiation of the retinal architecture (1). The inner retinal vasculature within the nerve fiber layer develops from spindle cell precursors that invade the nerve fiber layer starting at the optic disc and migrate peripherally along an advancing point of outer plexiform maturation (2). Retinopathy of prematurity occurs when there is the cessation of normal retinal vascularization. It shares pathophysiological cha-

racteristics with other ocular diseases such as diabetic retinopathy, age-related macular degeneration and central retinal vein occlusion. The process of retinal neovascularization in ROP and in animal models of oxygen-induced retinopathy is complex and involves angiogenic factors, such as vascular endothelial growth factor, and basement membrane components (3). We have performed ocular autopsies in order to explore retinal vascular development.

Aim of the study: to review the development of the retina and its vasculature and to present an unusual case of retinopathy of prematurity like changes found 26 hours after the birth of a premature infant.

MATERIALS AND METHODS

Fourteen eyes of seven autopsied fetuses and infants born during 17–36 gestational weeks were investigated. Autopsy was performed on the 1st–3rd days after birth.

* Correspondence to: Dr. Rasa Sirtautienė, MD, Dept. of Ophthalmology, Vilnius University Hospital, Santariškių 2, LT-08661 Vilnius, Lithuania. E-mail: rsirtautiene@walla.com

After enucleation, the eyes were embedded in 10% formaldehyde solution for 2 days. The eyeball was opened in horizontal section in the corneal center and optic nerve projection. After dehydration in the alcohols of increasing concentration, the specimen was embedded in paraffin. Staining with haematoxylin–eosin and Periodic Acid Schiff (PAS) was performed. The CD-31 immunohistochemical method was used to stain endothelial cells in the retina.

RESULTS

Histological studies on premature retina

Case I (Figs. 1, 2)

There is formation of the nerve fiber layer with ganglion cells, inner plexiform layer, neuroblastic layer, retinal pigment epithelium and choroidal vessels in autopsied two eyes at 17 weeks of gestation (birth weight (BW) 170 g).

Case II (Fig. 3)

The findings at the gestation age of 22 weeks (BW 400 g) show migration of the spindle-shaped cells in the nerve fiber layer, division of the neuroblastic layer into outer nuclear layer and inner nuclear layer and formation of the outer plexiform layer.

Normal inner retinal vasoformation

Case III

There are clearly seen three distinct zones of peripheral retina in two eyes of a premature infant with GA of 30 weeks and BW 1620 g:

- 1) vanguard retina with migration of spindle-shaped cells (Fig. 4) and cystoid spaces in avascular retina (Fig. 5),
- 2) interface with canalization of the spindle-shaped cells (Fig. 6),
- 3) rearguard retina with complete differentiation of spindle-shaped cells into endothelial cells (Fig. 7).

Case IV (Fig. 8)

Formation of the retinal vessels in the nerve fiber layer is seen at GA of 33 weeks and BW 1900 g.

Case V (Fig. 9)

There is complete vascularisation of the nasal retina of a premature with GA of 35 weeks and BW 2100 g. Blood vessels are clearly seen in the nerve fiber layer. There are neither spindle-shaped cells nor cystoid spaces (Fig. 9).

Case VI (Fig. 10)

Normal architecture of the retina (except macula) was found at gestation age of 36 weeks (BW 2300 g).

Case VII

Pathohistological examination of two eyes of an autopsied premature infant (GA 31 weeks, BW 1600 g) was performed. The baby died 26 hours after the delivery. Mother was diabetic, treated with insulin for many years.

In the nasal retina spindle shaped-cells, cystoid spaces surrounded by Muller's cells were seen towards the periphery (Fig. 11). Neither spindle-shaped cells nor

cystoid spaces were found in the vascular retina (Fig. 12).

There were seen two active zones in the nerve fibre layer in the temporal retina (Fig. 13):

- 1) thickening of the anterior (vanguard) retina-proliferation of primitive spindle shaped-cells (Fig. 14),
- 2) a rearguard zone with primitive endothelial cells (Fig. 15).

These changes of retina were identified 26 hours after the premature birth. This corresponds to the changes characteristic of stage I ROP.

DISCUSSION

The embryonic retina remains avascular until the fourth month of fetal development. The process of inner retinal vasoformation occurs as an orderly sequence of migration, canalization and differentiation of spindle-shaped cells into endothelial cells at a predictable time. These changes are going on evenly in normal retinal vasculogenesis. The capillary bed by the eight fetal month extends to the ora serrata nasally, but only to the equator temporally. The macula is often immature in full-term infants and virtually always immature in premature infants (4).

In case of a hazardous agent influence, which in most cases is hyperoxia, proliferative reaction of vasogenic tissue starts to develop. Thus, the first stage of ROP, i.e. demarcation line, is formed from hyperplastic spindle-shaped cells.

The development of similar changes lasts at least several weeks after birth. Various scientific studies claim that first ROP signs develop during the 4th to 6th week of chronological age (2).

The findings in the eyes in case VII resulted in a very unexpected outcome.

We were faced the fact which has never been described in the world's scientific literature, except N. Silaeva (5) who presented a pathohistologic examination of 74 fetuses and prematures, concluding that ROP starts antenatally.

Based on the changes that were tantamount to stage I ROP diagnosed in the infant 26 hours after birth, we presumed that ROP might start *in utero*. The reason for such event might be intrauterine hypoxia due to mother's diabetes or insulin treatment. Our presumption could be corroborated by the study of H. Chung et al. (6). They noted that "insulin treatment induced VEGF in rat retinal and RPE cell cultures as well as in rat ROP model. Insulin also increased endothelial cellular proliferation and aggravated retinal neovascularisation in this *in vivo* model".

Since the very beginning of the history of ROP, in 1943, Terry believed that ROP was most likely caused by a postnatal agent. Arguing that, in 1946, Reese contended that the disease must arise prenatally (7). It seems that the problem is not yet solved in spite of more than half a century of scientific development.

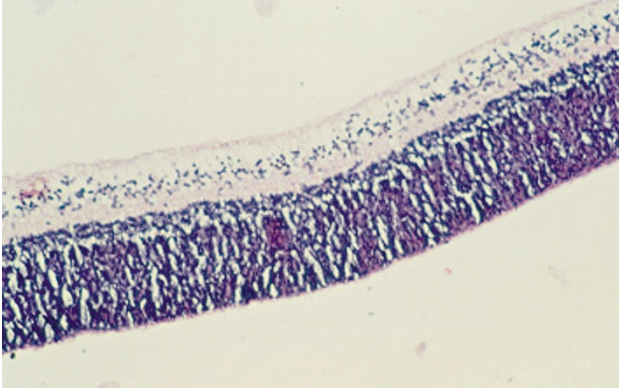


Fig. 1. GA 17 weeks. Formation of the nerve fiber layer with ganglion cells, inner plexiform layer, neuroblastic layer, retinal pigment epithelium and choroidal vessels (Hematoxylin-eosin (HE), magnification 50×)

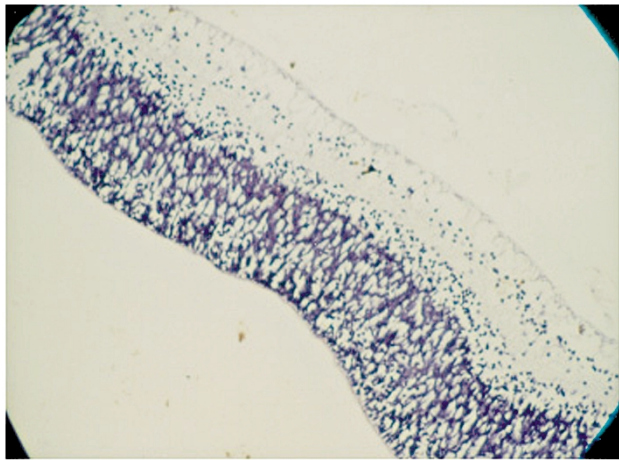


Fig. 3. GA 22 weeks. Migration of the spindle-shaped cells in the nerve fiber layer, division of the neuroblastic layer into outer nuclear layer and inner nuclear layer and formation of the outer plexiform layer (HE, 50×)

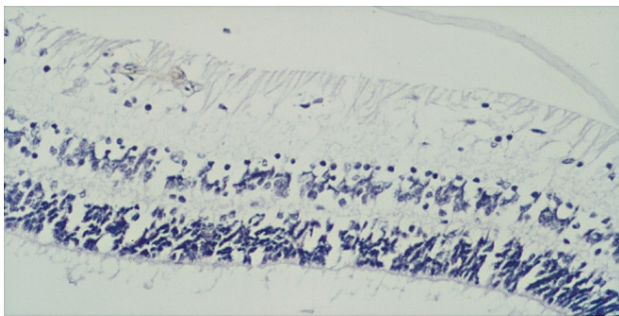


Fig. 6. GA 30 weeks. Interface with canalization of the spindle-shaped cells (HE, 50×)

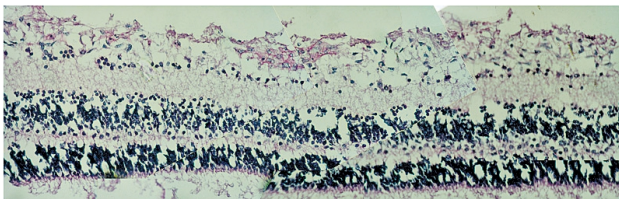


Fig. 7. GA 30 weeks. Rearward retina with complete differentiation of spindle-shaped cells into endothelial cells (HE, 50×)

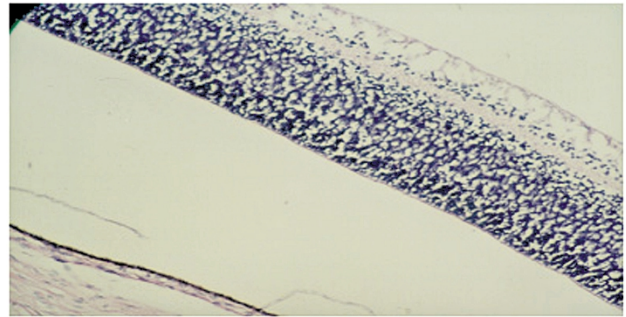


Fig. 2. GA 17 weeks. No vascularisation in the inner retina (HE, 50×)

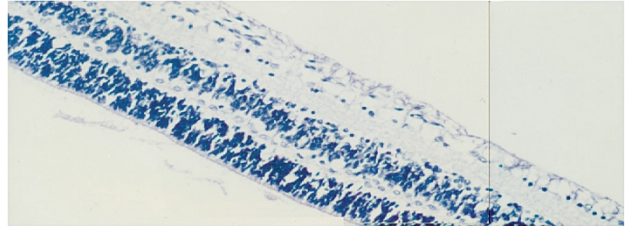


Fig. 4. GA 30 weeks. Vanguard retina with migrating spindle-shaped cells (HE, 50×)

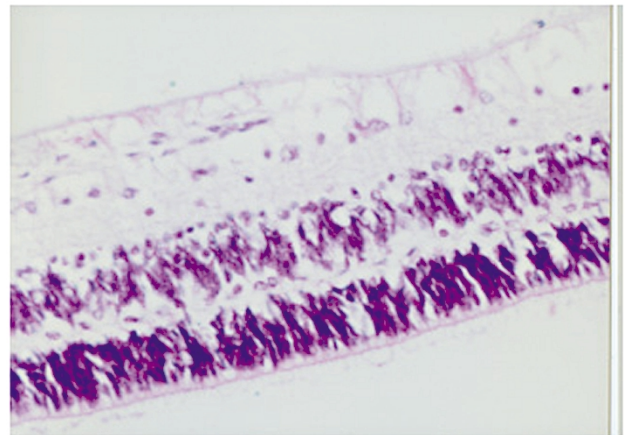


Fig. 5. GA 30 weeks. Cystoid spaces in avascular retina (HE, 100×)

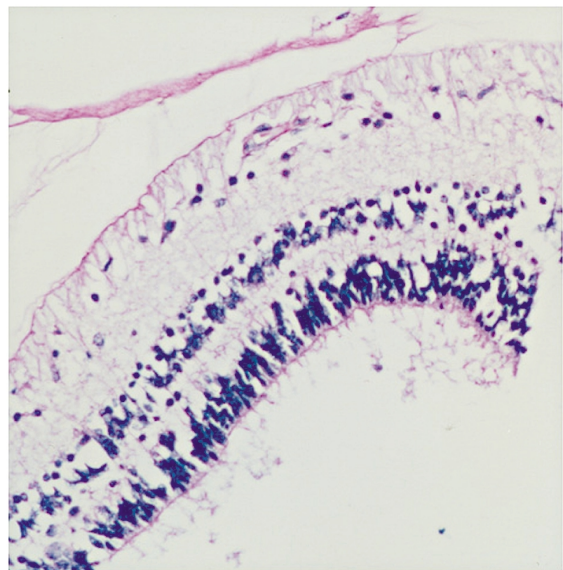


Fig. 8. GA 33 weeks. Formation of retinal vessels in the nerve fibre layer (HE, 100×)

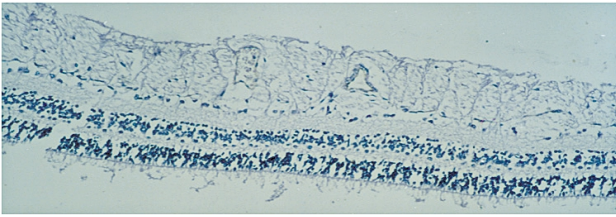


Fig. 9. GA 35 weeks. Complete vascularisation of the nasal retina of premature: blood vessels in nerve fiber layer. Spindle-shaped cells and cystoid spaces are absent (HE, 50×)

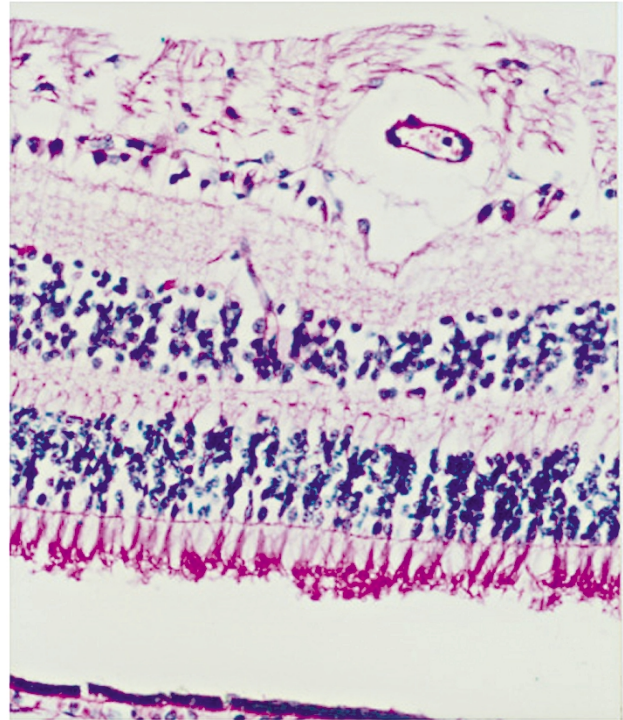


Fig. 10. GA 36 weeks. Normal structure of the peripheral retina (HE, 200×)

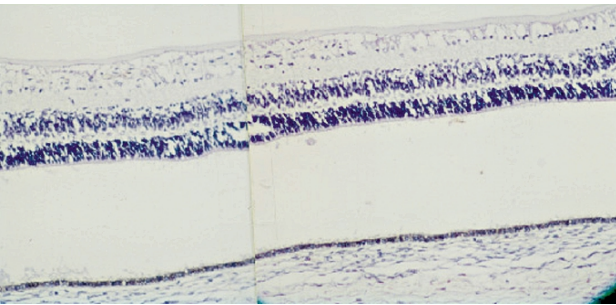


Fig. 11. Unusual case. GA 31 weeks. Spindle-shaped cells, cystoid spaces surrounded by Muller's cells, are seen towards periphery in the nasal retina (HE, 50×)

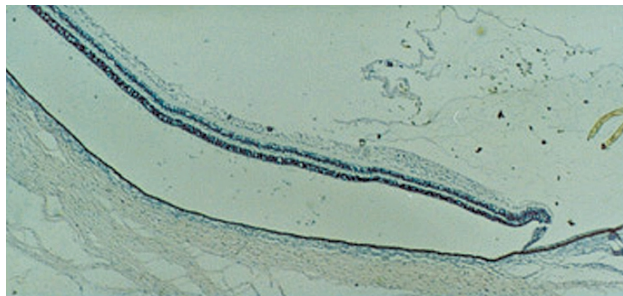


Fig. 13. Unusual case. GA 31 weeks. Two active zones in the nerve fibre layer in the temporal retina (HE, 8×)

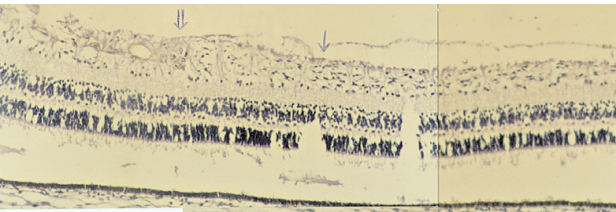


Fig. 12. Unusual case. GA 31 weeks. There are no spindle-shaped cells or cystoid spaces in vascular retina (HE, 50×)

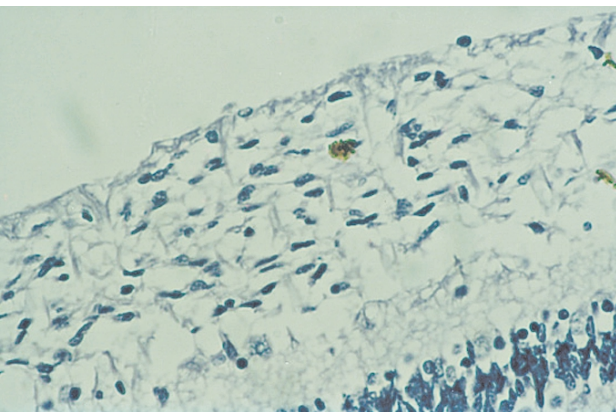


Fig. 14. Unusual case. GA 31 weeks. Thickening of the anterior (a vanguard) retina – proliferation of primitive spindle-shaped cells (HE, 200×)

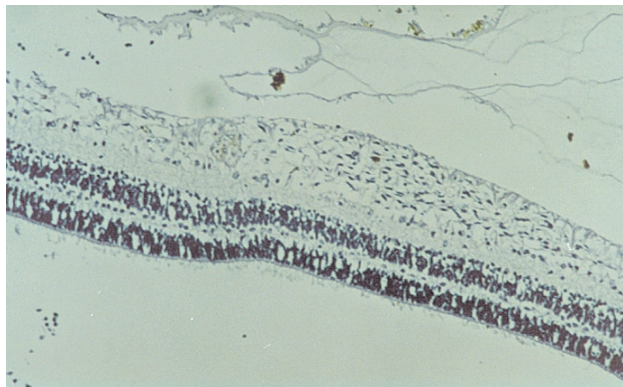


Fig. 15. Unusual case. GA 31 weeks. A rearguard zone with primitive endothelial cells (HE, CD-31, 50×).

CONCLUSIONS

Understanding of the retinal development and angiogenesis is necessary for appreciating the earlier stages of retinopathy of prematurity.

We speculate that the development of ROP is determined not only by postnatal but also by certain antenatal factors.

ACKNOWLEDGEMENT

Presented in part at ARVO (Association for Research in Vision and Ophthalmology) meeting 2005.

Received 6 June 2006

Accepted 31 July 2006

References

1. De Juan E, Jr. Retinopathy of prematurity. In: Freeman W.R. (ed.). *Practical Atlas of Retinal Disease and Therapy*. Raven Press, New York; 1997: 299–319.
2. Kretzer LF, Hittner MH. Human retinal development: relations to the pathogenesis of retinopathy of prematurity. In: McPherson A, Hittner MH, Kretzer LF (eds.). *Retinopathy of Prematurity*. B.C. Decker. Toronto, Philadelphia; 1986: 27–52.
3. Mechoulam H, Pierce EA. Retinopathy of prematurity: molecular pathology and therapeutic strategies. *Am J Pharmacogenomics* 2003; 3(4): 261–77.
4. Ben Sira I, Nissenkorn I, Kremer I. Retinopathy of prematurity. Major review. *Surv Ophthalmol* 1988; 33(1): 1–16.
5. Silajeva NF. *Vestn Ophthalmol (Rus)* 1990; 106(2): 22–5.
6. Chung H, Yoo M, Koh JY, Kim JG, Yoon Y. Insulin upregulates VEGF and aggravates retinopathy of prematurity in newborn rats. *Invest Ophthalmol Vis Sci* 46 (E-Abstract): 3256.
7. Jakobson RM, Feinstein AR. Oxygen as a cause of blindness in premature infants: “autopsy” of a decade of errors in clinical epidemiologic research. *J Clin Epidemiol* 1992; 45(11): 1265–87.