

# Antiarthritic and hepatoprotective effect of derinat on adjuvant arthritis in rats

Laima Leonavičienė,

Eiva Bernotienė,

Rūta Bradūnaitė,

Dalia Vaitkienė,

Elvyra Redaitienė,

Vytautas Astrauskas

*Institute of Experimental and  
Clinical Medicine of  
Vilnius University,  
Vilnius, Lithuania*

**Background:** The inclusion of immunomodulators into the schemes of the treatment of autoimmune process, especially under the therapy with immunosuppressive preparations, is motivated because immunological disturbances play an essential role in the pathogenesis of these conditions. The aim of the present study was to provide data regarding the antiarthritic effect of immunomodulator derinat (D) alone and in combination with methotrexate (MTX), to compare the obtained results with the effects of MTX alone, and to evaluate the potential properties of D to reduce the hepatotoxicity of MTX.

**Materials and methods:** 60 Wistar rats with adjuvant arthritis (AA) were treated with D alone in doses of 6 mg/kg or 18 mg/kg, with a combination of either of them with 2 mg/kg of MTX or MTX alone (2 mg/kg). MTX once a week and D five times a week were injected intramuscularly (i. m.). Control group received saline. The duration of experiment was 17 days.

**Results:** Joint swelling and the histological parameters of arthritis in adjuvant-injected paws were significantly suppressed by all kinds of the treatments tested. D was the most effective TNF- $\alpha$  suppressor and accelerator of lymphocyte blasttransformation. MTX and D did not act synergistically and the antiarthritic effect was not aggravated when the treatment was combined. However, D exerted a positive effect on MTX-elicited alterations in liver.

**Conclusions:** Our results have shown that anti-inflammatory and antiarthritic properties of D on AA in rats are comparable to those exerted by low doses of MTX. D attenuated MTX-induced toxicity on liver, suggesting that the use of combined treatment with MTX and D might also be expedient.

**Key words:** adjuvant arthritis, derinat; methotrexate

## INTRODUCTION

Rheumatoid arthritis (RA) is a chronic autoimmune disease characterized by a severe immune pathology which leads to irreversible joint destruction and damage when left untreated. The therapy of RA remains one of the most actual problems of modern rheumatology, because in a great number of cases the best therapeutic efforts do not give expected results and are often associated with numerous complications and serious side effects (1). Even though numerous new biologic agents for the treatment of RA are constantly emerging, there is still an emphatic role for traditional DMARDs (2, 3). Nevertheless, despite the long-term treatment with traditional therapy, the disease in some cases shows a resistant course with expressed inflammation of synovium and progressive joint destruction (4). Therefore, combined

therapy is widely used, although with varying success (5, 6). Our previous investigations on rats with adjuvant arthritis (AA) showed that combined therapy of MTX with sulfasalazine, azathioprine, IFN- $\gamma$  was more effective than monotherapy (7, 8).

MTX alone or in combination has become accepted as an ideal treatment for active RA, but the positive effect is achieved not in all patients (9). Therapy with MTX is associated with a high incidence of dose-dependent toxicity (10), including elevations in liver function enzymes, bone marrow suppression and gastrointestinal mucosal inflammation (10, 11). Opportunistic infections are also increasingly reported in RA treated with MTX (12).

Treatment with MTX is usually supplemented with folic and folinic acid which are known to reduce MTX toxicity (13). However, the anti-inflammatory action of low-dose MTX in the treatment of RA appears to be partially impaired by folate supplementation as all the antiproliferative, cytotoxic, and monocyte differentiating effects of MTX were completely reversed by folinic acid (14).

Correspondence to: Laima Leonavičienė, Institute of Experimental and Clinical Medicine of Vilnius University, Žygmantų 9, LT-01102 Vilnius, Lithuania. E-mail: laima.leonavi-ciene@ekmi.vu.lt

The inclusion of immunomodulators into the schemes of treatment of the autoimmune process, especially under the therapy with immunosuppressive preparations, is motivated (15), because the immunological disturbances such as deficit of lymphoid cells, decrease of non-specific immunity and others, play a key role in the pathogenesis and natural history of these conditions.

Derinat (D) is a sodium salt of native DNA, extracted from the soft roes of sturgeons. D is often called a unique Russian immunomodulator as it has been produced exclusively in Russia and used predominantly in Russia for the treatment of patients with an abundant variety of indications in almost all fields of medicine (16–18). Unfortunately, most of available information on D is in the Russian language. The results of treatment with D, as a rule, are reported to be incredibly good, including those observed in pediatric patients (19). Moreover, a low toxicity (the LD<sub>50</sub> value for intraperitoneal administration exceeds 1000 mg/kg) and very rare side effects are reported (20). The effect of DNA is claimed to depend on the degree of polymerisation, its molecular weight must not exceed 500 kDa, only a native form of DNA is biologically active and being a sodium salt is compulsory for maintaining homeostasis in the cell (21). The idea of treatment with DNA originates from the turn of the 19th–20th centuries (17). Nowadays D is used in the clinical practice for treatment of radiation sickness, various infections and sepsis, tumors and other diseases associated with conditions of immunodeficiency (16–18). D is claimed to exert a strong immunomodulatory activity such as to stimulate reparation, regeneration, to stabilize hemopoiesis, to show an active antibacterial, antiviral, antifungal and antitumor action and overall to normalize the immune system (21). However, to the best of our knowledge, the potential antiarthritic effect of D has never been investigated. As D was described to display hepatoprotective properties (16, 22) and MTX-induced liver damage is an important complication in patients treated with this drug (23), D might appear to be an attractive candidate for controlling hepatotoxicity exerted by MTX. To test these indications, we used adjuvant arthritis (AA) in rats, a classic experimental model of polyarthritis, which is widely used for testing antiarthritic agents, as it shares similarities with RA in humans (24).

The aim of the present study was to provide data regarding the antiarthritic effect of immunomodulator D alone and in combination with MTX and to compare to that of MTX alone. We were also seeking to evaluate the potential properties of D to reduce the hepatotoxicity of MTX when used in combination on rats with AA.

## MATERIALS AND METHODS

### *Animals*

Sixty Wistar male rats weighing 240–300 g were purchased from Bioreglament (Vilnius, Lithuania) and kept

for acclimation to the environment for one week before the experiment was started. The animals were housed under standard conditions and had free access to standard rat chow and water throughout the study. Approval of the Ethic Committee for Laboratory Animal Use, Lithuania, was obtained prior to commencement of the manipulations on animals.

### **Induction of arthritis, drugs and treatment schedule**

The animals were divided into six equal groups (10 animals per group). 0.1 ml of complete Freund adjuvant (Calbiochem, USA) was injected intraplantarly into the footpad of the left hind paw of all animals used in this study, including the control group.

The following drugs, alone or in combination, were used throughout the study: MTX (Ebewe, Austria) once a week and D (CJS FP; Technomedservis, Russia) 5 times a week were injected intramuscularly (i.m.). Treatment was started on the day of AA induction and continued till day 16. Separate groups of animals received D alone in doses of 6 mg/kg or 18 mg/kg, either of those two doses of D in combination with MTX (2 mg/kg), or MTX (2 mg/kg) alone. Control group received i.m. injections of sodium saline.

### **Body weight and paw swelling assessment**

To follow the course of the disease, swelling of the adjuvant-injected hind paw was determined plethysmographically. Body weight and paw volume were measured three times a week and the percentage deviation from the control group was calculated. The incidence of polyarthritis development is presented as a percentage of animals per group with at least one joint swollen in a non-injected paw.

### **Sacrifice and determination of blood indices, TNF $\alpha$ concentration and blasttransformation of lymphocytes**

On day 17 after AA induction, the animals were sacrificed by decapitation under anesthesia; blood hind paws, and liver samples were collected for investigation. Leukocyte and erythrocyte count with a Picoscale hematological analyzer (Hungary) and ESR were determined.

TNF $\alpha$  concentration in blood serum was measured with OPTELA RAT TNF $\alpha$  ELISA kit (PharMingue, USA) according to the manufacturer's instruction.

Blasttransformation of spleen lymphocytes to phytohemagglutinin (PHA) (lectin from *Phaseolus vulgaris*, Type P; Serva, New York, USA) was evaluated morphologically. Ficol gradient was used to purify rat spleen lymphocytes. Cells were washed twice with PBS and resuspended in 1 ml RPMI 1640; 50  $\mu$ l of mitogen PHA and 200  $\mu$ l of calf serum were added to  $5 \times 10^6$  cells and with RPMI volume adjusted to 1 ml/tube. Following cultivation for 72 h at 37 °C, the cells were centrifuged and smears stained by the Giemsa-Romanowski method. The percentage of morphologically determined blast cells was calculated.

### Histological examination

Rats were sacrificed on day 17 after the injection with Freund's adjuvant. Their liver and the ankles of adjuvant-injected paws were examined histologically in groups of rats treated with D (6 mg/kg) alone, D (18 mg/kg) in combination with MTX, MTX alone and in the control group. Ankle joints were fixed in 10% formalin, liver samples in spirit-formol. Following decalcification in 10% nitric acid (HNO<sub>3</sub>) and paraffin embedding, the specimens of joints were cut on a microtome at multiple levels. Histological sections of joints and liver were stained with hematoxylin-eosin (for visualization of cells), picrofuxin, toluidine blue (for visualization of proteoglycan loss and cartilage damage), methyl-green-pyronin-9 (plasmatisation), periodic acid-schiff reagent (PAS reaction), and safranin O (for evaluation of changes in cartilage).

Histological assessment of inflammatory infiltration with lymphocytes, plasma cells, macrophages and granulocytes and of various other inflammatory symptoms in liver, synovium and soft periarticular tissues as well as evaluation of cartilage damage were performed in a blinded manner. A 4-point score (0–3) was used, where 0 indicates the absence of changes and 3 is the most severe expression of a particular symptom.

### Statistical analysis

The results were expressed as mean values  $\pm$  SEM. Differences between control and treated groups were statistically analyzed by Student's t test and  $p < 0.05$  was considered statistically significant. The percentage deviation of the treated group data from the control was derived by the following formula:  $(T-C)/C \times 100$ , where T is the data on one of the treated groups and C is the data on the control or MTX-treated group.

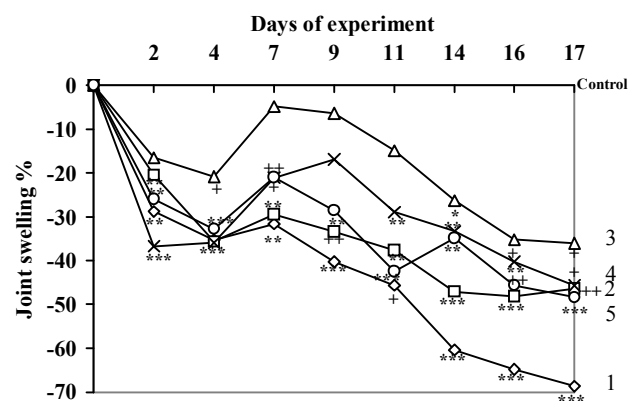
## RESULTS

In this study, we investigated the effect of monotherapies with D or MTX and of their combined treatment on AA in rats and compared the results with those in saline-treated control group. AA was induced in all animals involved in this study. No signs of general toxicity from any of administered drugs were determined, all animals survived and continued to grow. At the end of experiment the body weight gain, indicating recuperation from disease, tended to

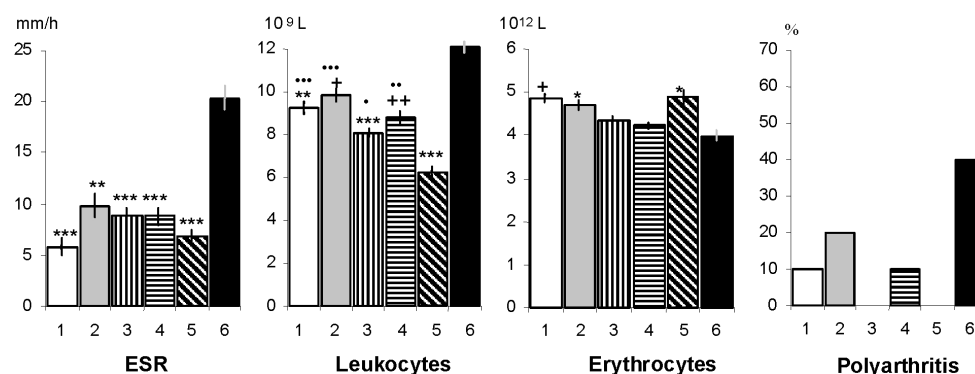
be higher in all groups receiving treatment, while in rats receiving monotherapy with D (6 mg/kg) the difference even reached scientific significance ( $p < 0.05$ ) (data not shown).

### Swelling measurement in the adjuvant-injected paw

Development of inflammation was followed by measuring plethysmographically the volume of adjuvant-injected paw three times per week. Paw swelling was significantly suppressed by all kinds of test treatments (Fig. 1). The best effect was achieved in rats that received 6 mg/kg of D, in which on days 14–17 of the experiment the volume of the swollen paw was considerably smaller than that in the MTX-treated group ( $p < 0.05$ –0.01).



**Fig. 1.** Joint swelling in rats with adjuvant arthritis treated by various doses of derinat (D) and its combination with methotrexate (MTX) (mean indices of joint swelling are expressed as percentages from mean indices in the arthritic control). 1 – D (6 mg/kg), 2 – D (18 mg/kg), 3 – D (6 mg/kg) + MTX (2 mg/kg), 4 – D (18 mg/kg) + MTX (2 mg/kg), 5 – MTX (2 mg/kg), 6 – control (sodium saline). Differences are significant in comparison with the control group. \*  $p < 0.05$ ; \*\*  $p < 0.01$ ; +  $p < 0.02$ ; ++  $p < 0.002$ ; \*\*\*  $p < 0.001$ .



**Fig. 2.** Blood indices and polyarthrititis in rats with adjuvant arthritis treated by various doses of derinat and its combination with MTX. 1 – D (6 mg/kg), 2 – D (18 mg/kg), 3 – D (6 mg/kg) + MTX (2 mg/kg), 4 – D (18 mg/kg) + MTX (2 mg/kg), 5 – MTX (2 mg/kg), 6 – control (sodium saline). Differences are significant in comparison with the control group (\*  $p < 0.05$ ; \*\*  $p < 0.01$ ; +  $p < 0.02$ ; ++  $p < 0.002$ ; \*\*\*  $p < 0.001$ ) and MTX treated group (•  $p < 0.02$ ; ••  $p < 0.01$ ; •••  $p < 0.001$ ).

However, the use of the same dose (6 mg/kg) of D in combination with MTX did not reinforce swelling suppression and was even somewhat less effective than either monotherapy applied. A higher dose of D (18 mg/kg) alone or in combination with MTX showed a similar effect to that of MTX alone throughout the study.

### Incidence of polyarthritis development

Development of polyarthritis, characterizing generalisation of the disease and exacerbation of the autoimmune process, was completely abolished in groups treated with MTX alone and its combination with D in the dose of 6 mg/kg (Fig. 2). It developed in 10% of rats that received 6 mg/kg of D or 18 mg/kg of D + MTX, in 20% of the animals administered 18 mg/kg of D alone and in 40% of the controls.

### Blood indices

Blood indices improved under all kinds of treatment, while in the control group they were reflecting a severe inflammatory response as determined on day 17 of AA (Fig. 2). In healthy rats, erythrocyte count was  $5.4\text{--}8.5 \times 10^{12}/\text{l}$ , leukocyte count being  $4\text{--}10.2 \times 10^9/\text{l}$  and ESR 1–4 mm/h. In all treated groups we observed a markedly lower ESR and leukocyte count and a higher erythrocyte count as compared with the control group with untreated AA. Leukocyte count returned to normal under all kinds of treatment, while the most pronounced effect was shown by MTX monotherapy.

### Serum TNF $\alpha$ levels

Serum TNF $\alpha$  was strongly elevated in all rats on day 17 of AA (Table 1). However, as compared to the

Table 1. Changes in the level of serum TNF $\alpha$  and blasttransformation of spleen lymphocytes (LBT) to phytohemagglutinin in rats with adjuvant arthritis treated with methotrexate and its combination with derinat

Groups	Indices	
	TNF $\alpha$ (pg/ml)	LBT (%)
D (6 mg/kg)	*20.6 $\pm$ 8.33	***22.43 $\pm$ 3.03***
D (18 mg/kg)	29.5 $\pm$ 4.33	-
MTX (2 mg/kg/w) + D (6 mg/kg)	34.8 $\pm$ 5.95	-
MTX (2 mg/kg/w) + D (18 mg/kg)	33.9 $\pm$ 5.74	*11.43 $\pm$ 1.06**
MTX (2 mg/kg/w)	38.9 $\pm$ 2.59	8.29 $\pm$ 0.91
Control (sodium saline)	38.6 $\pm$ 6.51	5.40 $\pm$ 1.07

Note. Data represent mean values  $\pm$  SEM, n = 10. Derinat (D) was injected i.m. 5 times a week and methotrexate (MTX) – 2 mg/kg i.m. once a week. Symbols on the right – the differences are significant between control and test groups. Symbols on the left – the differences are significant in comparison with MTX group \* p < 0.05; \*\* p < 0.01; \*\*\* p < 0.001.

saline-treated control group, it was lower in all groups given D alone or in combination with MTX. Interestingly, the most considerable reduction of TNF $\alpha$  was observed under the monotherapy with D, especially in the group receiving 6 mg/kg in which TNF $\alpha$  was reduced by 46.6%. Treatment with a higher dose of D (18 mg/kg) reduced serum TNF $\alpha$  levels by 23.5%. However, no reduction of serum TNF concentration was observed in the MTX-alone-treated group, whereas it tended to be lower under the combined treatment with either dose of D (6 mg/kg and 18 mg/kg) and MTX as compared to the control group.

### Lymphocyte blasttransformation

Accelerated lymphocyte blasttransformation to nonspecific mitogen PHA, indicating recuperation of lymphocyte function, has been registered in all test groups, while under the treatment with MTX alone the increase did not reach scientific significance (Table 1). The most pronounced effect, a four-fold increase in lymphocyte blasttransformation, was observed in rats receiving D (6 mg/kg); as compared with control animals, the effect was less expressed when D was used in combination with MTX. Moreover, it was also significantly more intensive under monotherapy with D (6 mg/kg) than under monotherapy with MTX.

### The effect of treatment on the liver

Following the onset of autoimmune stage, AA itself is associated with alterations in liver (25). A pathomorphological examination of liver in the control rats with AA showed V. centralis hypervolemia, alterations in hepatocytes and inflammatory response (Table 2). Fatty dystrophy, basophilic degeneration and vacuolization of some hepatocytes were observed. The inflammatory cell infiltration of hepatic stroma was not grave in adjuvant-injected controls, while it was still lower under all kinds of treatments applied. MTX exacerbated parenchyma alteration in liver (p < 0.05), whereas D alone showed no signs of hepatotoxicity and, when used in combination, exerted a positive effect on MTX-elicited alterations in liver. Moreover, fibrotic changes in liver, which are common adverse effects of MTX (23), were strongly augmented by monotherapy with the drug in our study, and the use of combined treatment with D was also beneficial.

### Arthritis significantly suppressed by all kinds of treatment

Histological examination of ankle joints in the control group on day 17 after AA induction showed an expressed inflammatory cell infiltration, proliferation of new capillars, mucoid edema and foci of fibrinoid necrosis in both synovium (Fig. 3A) and soft tissues surrounding the joints (Table 3). These indices were considerably improved by D (Fig. 3B), MTX or their combination. Synovium villous proliferation and expansion were also significantly attenuated by all the treatments as compared to the control.

Table 2. Effect of methotrexate, derinat or their combination on histological changes in the liver of rats with adjuvant arthritis

Morphological changes	Groups			
	D (6 mg/kg)	MTX (2 mg/kg/w) + D (18 mg/kg)	MTX (2 mg/kg/w)	Control (sodium saline)
Alteration of parenchyma	$^{+}1.3 \pm 0.10$	$1.5 \pm 0.04$	$1.7 \pm 0.11^{+}$	$1.3 \pm 0.10$
Hypervolemia of V.centralis	$0.7 \pm 0.27$	$0.6 \pm 0.15$	$0.7 \pm 0.18$	$1.1 \pm 0.19$
General inflammatory reaction	$0.2 \pm 0.09^{*}$	$0.3 \pm 0.12$	$0.2 \pm 0.09^{*}$	$0.7 \pm 0.19$
Fibrosis	$0.6 \pm 0.18$	$0.6 \pm 0.18$	$1.1 \pm 0.13^{*}$	$0.6 \pm 0.15$

Note. Data shown represents mean values  $\pm$  SEM, n = 10. Derinat (D) was injected i.m. 5 times a week and methotrexate (MTX) – 2 mg/kg i.m. once a week. Symbols on the right – the differences are significant between control group and test group. Symbols on the left – the differences are significant in comparison with MTX. group \* p < 0.05; + p < 0.02.

Table 3. Pathomorphological changes in joints of rats with adjuvant arthritis treated with methotrexate and its combination with derinat

Morphological changes	Groups			
	D (6 mg/kg)	MTX (2 mg/kg/w) + D (18 mg/kg)	MTX (2 mg/kg/w)	Control (sodium saline)
<b>Soft periarticular tissues</b>				
General inflammatory infiltration	$1.30 \pm 0.14^{***}$	$1.40 \pm 0.10^{***}$	$1.20 \pm 0.12^{***}$	$2.60 \pm 0.13$
Edema	$0.80 \pm 0.10^{***}$	$0.70 \pm 0.11^{***}$	$0.60 \pm 0.15^{***}$	$1.90 \pm 0.07$
Angiomatosis	$0.90 \pm 0.05^{***}$	$0.80 \pm 0.13^{***}$	$0.90 \pm 0.10^{***}$	$1.80 \pm 0.21$
$\gamma$ -metachromasia	$0.30 \pm 0.10^{+}$	$0.30 \pm 0.09^{+}$	$0.30 \pm 0.10^{+}$	$0.70 \pm 0.12$
<b>Synovium</b>				
Villous proliferation	$0.70 \pm 0.10^{***}$	$0.70 \pm 0.11^{***}$	$0.70 \pm 0.09^{***}$	$1.90 \pm 0.12$
Edema	$0.30 \pm 0.10^{***}$	$0.20 \pm 0.11^{***}$	$0.20 \pm 0.10^{***}$	$1.20 \pm 0.20$
General inflammatory infiltration	$0.40 \pm 0.05^{***}$	$0.50 \pm 0.10^{***}$	$0.30 \pm 0.08^{***}$	$1.90 \pm 0.16$
Angiomatosis	$0.80 \pm 0.13^{***}$	$0.90 \pm 0.11^{***}$	$0.90 \pm 0.14^{***}$	$2.00 \pm 0.06$
$\gamma$ -metachromasia	$0.20 \pm 0.10$	$0.10 \pm 0.06^{*}$	$0.10 \pm 0.06^{*}$	$0.40 \pm 0.13$
Fibrosis	$^{**}1.40 \pm 0.17^{***}$	$1.90 \pm 0.11^{***}$	$2.00 \pm 0.08^{***}$	$0.40 \pm 0.17$
<b>Cartilage</b>				
Erosium	$0.60 \pm 0.17$	$0.60 \pm 0.18$	$0.80 \pm 0.15$	$1.10 \pm 0.32$
Usure	$0.20 \pm 0.12$	$0.20 \pm 0.09$	$0.10 \pm 0.20$	$0.80 \pm 0.33$
Pannus	$0.10 \pm 0.07^{**}$	$0.30 \pm 0.15$	$0.10 \pm 0.05^{**}$	$0.80 \pm 0.21$
Thinning of cartilage	-	$0.20 \pm 0.09$	-	$0.30 \pm 0.15$

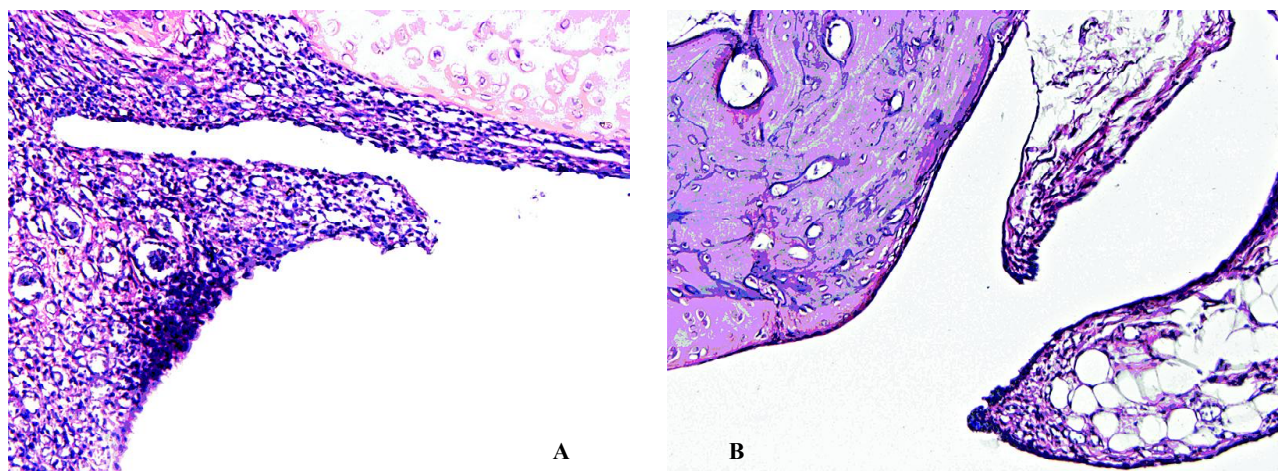
Note. Data represent mean values  $\pm$  SEM, n = 10. Derinat (D) was injected i.m. 5 times a week and methotrexate (MTX) 2 mg/kg i.m. once a week. Symbols on the right – the differences are significant between control and other test groups. Symbols on the left – the differences are significant in comparison with MTX group. \* p < 0.05; \*\* p < 0.01; \*\*\* p < 0.001; + p < 0.02.

Fibrotic changes, reflecting the healing process and recuperation of inflammation, were considerably more vivid under all kinds of treatment, also in both synovium and periarticular tissues, while they were more pronounced in the groups receiving MTX alone or in combination with D. All the tested treatments showed a similar beneficial effect on cartilage damage and the growth of pannus.

## DISCUSSION

In the present study, treatment with both doses of D alone, their combination with MTX or MTX alone showed a significant amelioration of AA in rats.

AA is known to manifest by a course of two waves of joint swelling, the first wave being related to non-immune inflammation, while the second wave, starting after two weeks, depends on the immune response, especially a cell-mediated one. We observed a considerable reduction of swelling in adjuvant-injected rat paws and thereby joints, starting from day 2 and throughout the experiment, indicating both the anti-inflammatory and the immune response-attenuating properties of all the treatments tested. Improvement of the blood indices and a histologically determined significant shrinking of arthritis symptoms were registered on day 17 of AA. Changes in periarticular tissues, synovium and cartilage were



**Fig. 3.** Histology of ankle joints of rats with adjuvant arthritis on day 17. A representative section of ankle joint in Freund's adjuvant-injected left hind paw of untreated rat from **control group (A)** and that of a rat treated with **6 mg/kg of D (B)** are demonstrated; hematoxylin–eosin stain, magnification  $\times 100$ . While pronounced inflammatory cell infiltration and synovial hyperplasia were observed in the control group, ankle joints of treated rats displayed a discrete inflammatory cell infiltration associated with a slight synovial hyperplasia. Histology showed similar articular lesions in all groups that received treatment with D alone, its combinations with MTX or MTX alone

successfully controlled by either monotherapy as well as by combined treatment. Interestingly, D in a dose of 6 mg/kg produced an even significantly stronger suppression of paw swelling than did MTX, though the effect was not dose-dependent as it was less pronounced under the treatment with a higher dose of D. Similarly, weight gain, which is usually associated with remission of the disease, was most pronounced in the group that received 6 mg/kg of D. Moreover, D appeared to be the most effective TNF $\alpha$  suppressor and accelerator of lymphocyte blast transformation to nonspecific mitogen PHA as compared to the MTX or combined treatment. Nevertheless, although the latter properties were outweighed by D, the histology of adjuvant-injected paws revealed no advantages of D treatment versus that of MTX on day 17 of AA. There were no essential differences in arthritis severity among all the groups, while it was significantly weaker when compared to the controls. D was also not distinct in the reduction of polyarthritis development frequency, which was similarly attenuated under all kinds of treatment. The discrepancies between the results of paw swelling measurements and histology data might reflect the involvement of different extent areas by the inflammation of the same severity and thus a limited expansion of inflammation under the treatment with D. However, in our study, MTX was given in a relatively low dose and the enhancement of its effect could be expected by increasing the dose. Surprisingly, the augmentation of D dose was not expedient. Taken together, our data suggest that the monotherapy with either dose of D (6 mg/kg or 18 mg/kg) was at least not less efficient than treatment with MTX in a dose of 2 mg/kg on AA in rats. The result is interesting, taking into account that MTX continues to be used as the first choice disease-modifying antirheumatic drug in RA (26).

The significance of TNF $\alpha$  in mediating the arthritogenic response has been demonstrated in animal models of arthritis (27) and in patients with RA (28). TNF $\alpha$  increases synoviocyte proliferation and triggers the release of secondary mediators involved in the recruitment of inflammatory cells, in neoangiogenesis and in the process of joint destruction (28). MTX is demonstrated to modulate TNF $\alpha$  production *in vitro* (29). *In vivo* and *ex vivo* MTX has minor (reduce) or no effects on TNF $\alpha$  production by blood mononuclear cells (30, 31) and stimulates the soluble TNF receptor p75 (30). Some authors suggest that perhaps MTX decreases TNF $\alpha$  production locally in the synovium, so they do not see an effect of MTX therapy on TNF $\alpha$  concentration in the peripheral blood (3, 30). It has also been shown that in animal models MTX decreases synovial fluid TNF $\alpha$  concentrations (32). In the blood serum of rats we observed no changes in TNF $\alpha$  levels after treatment with MTX, and the low dose and the short treatment course might serve as an explanation for that. On the other hand, that is in agreement with the elsewhere published data when TNF $\alpha$  levels remained elevated despite the MTX-induced disease remission (33).

At the same time, the modulation of TNF $\alpha$  production might partly enlighten the mechanism of action of D. These data, together with the recuperated lymphocyte function in rats with AA receiving D, further support the strong immunomodulative properties of D, while additional thorough investigations are needed to clarify the mechanism of action of the preparation.

Our study was designed to evaluate the antiarthritic properties of not only D alone, but also of combined treatment with MTX as well. A 3 mg/kg dose of MTX in rats gives the serum level of  $0.6 \pm 0.2$  mmol which corresponds to the level attained in humans five hours following a standard "rheumatoid arthritis dose" of MTX

( $0.5 \pm 0.2$  mmol) (34). We have chosen the lower dose of 2 mg/kg of MTX, which could allow detection of the additional favorable activity of D.

In contrast to our expectations, MTX and D did not act synergistically and the antiarthritic effect was not enhanced when the combined treatment was applied. Neither paw swelling measurements nor histological scoring revealed any improvement while comparing to the results of either monotherapy. Some confrontation between the two effects might have occurred, as MTX is an inhibitor of folic acid synthesis and thereby of protein synthesis, while D, on the contrary, might reinforce the proliferation of cells and immune processes.

In addition to the antiarthritic effect, we were seeking to evaluate the anti-hepatotoxic properties of D as another indication for using combined treatment with MTX and D. The toxicity of disease-modifying agents, including MTX, often limits the dose and / or duration of therapy (35, 36). By using the combined therapy, we expected to diminish the toxicity of MTX, as the hepatoprotective properties of D have been reported (22). Similarly to the elsewhere published data (23), MTX exerted a toxic effect on liver as demonstrated by a significantly exacerbated parenchyma alteration and fibrosis in addition to that observed in the control. The effect was not detected in D-treated group and was attenuated when MTX was combined with D. These results suggest a protective effect of D on MTX-induced liver injury, though studies with higher doses and prolonged courses of MTX are needed to postulate that.

Infection processes, which complicate the course of primary disease, are considered to be one of the reasons for using immunomodulators in autoimmune diseases (15). D is described to activate anti-infectious immunity (18). Although a low dose of MTX was also reported to be associated with infectious complications (12), in our experiment the course of treatment with MTX was too short for their manifestation and thus for the evaluation of the protective properties of D. Experiments of longer duration are needed to investigate this indication for the use of D in combination with MTX or other immunosuppressive drugs. Although the evidence of D effectiveness is not always convincing and scientifically based approvals in many cases are lacking, our results are in line with the data reviewed in the introduction, in the sense that D exerted beneficial immunomodulatory effects. The immune system is disturbed in RA, and D might appear to be a useful tool to eliminate the disbalance as well as to combat the adverse effects commonly caused by antirheumatic agents.

In conclusion, our data showed that the immunomodulator D displays anti-inflammatory and antiarthritic properties on AA in rats, which are comparable to those exerted by a low dose of MTX. The effect of D is not dose-dependent. D itself showed no adverse effects and possessed a capacity to attenuate MTX-induced toxicity on liver, thus showing a combined treatment with MTX and D to be expedient. The abilities to inhibit TNF $\alpha$

and to stimulate lymphocyte blasttransformation suggest that the protective effect of D on AA in rats might be mediated via modulation of the immune system and correction of cytokine imbalance. However, further investigations are needed to clarify the mechanism of action of D and to confirm its efficacy in the studies of longer duration and in combination with the higher doses of MTX.

## ACKNOWLEDGEMENTS

We wish to express our thanks to Biomedservis and Dr. Dalia Stasytytė for the presentation of Derinat. We are grateful to Jolita Tamulevičienė for the laboratory and Tomas Bileišis for the technical help when preparing the manuscript.

Received 10 October 2006  
Accepted 14 November 2006

## References

1. Tugwell P, Welch V, Suarez-Almazor M, Shea B, Wells G. Efficacy and toxicity of old and new disease modifying antirheumatic drugs. *Ann Rheum Dis* 2000; 59(Suppl 1): 32–5.
2. Cannella AC, O'Dell JR. Is there still a role for traditional disease-modifying antirheumatic drugs (DMARDs) in rheumatoid arthritis? *Curr Opin Rheumatol* 2003; 15(3): 185–92.
3. Swierkot J, Szechinski J. Methotrexate in rheumatoid arthritis. *Pharmacol Rep* 2006; 58(4): 473–92.
4. Mottonen T, Hannonen P, Leirisalo-Repo M, Nissila M, Kautiainen H, Korpela M. Comparison of combination therapy with single-drug therapy in early rheumatoid arthritis: a randomized trial. *Lancet* 1999; 353: 1568–73.
5. Venalis A, Dadoniene J. Treatment of severe rheumatoid arthritis combining methotrexate, azathioprine and sulphasalazine with antimalar drugs. *Acta medica Lituanica* 1996; 2: 57–62.
6. Simon LS. DMARDs in the treatment of rheumatoid arthritis: current agents and future developments. *Int J Clin Pract* 2000; 54: 243–9.
7. Leonaviciene L, Astrauskas V, Venalis A, Bradunaite R, Vaitkiene D, Filipaviciute R. Effect of recombinant alpha<sub>2</sub>- and gamma-interferons and their combinations with chemotherapy on the development of adjuvant arthritis in rats. *Acta medica Lituanica* 1999; 6: 46–54.
8. Bradunaite R, Leonaviciene L, Venalis A, Vaitkiene D, Astrauskas V. Azathioprine in combined therapy. Experimental treatment of autoimmune process. *Acta medica Lituanica* 2001; 8: 105–14.
9. Alarcon GS, Bartolucci AA. Radiographic assessment of disease progression in rheumatoid arthritis patients treated with methotrexate or minocycline. *J Rheumatol* 2000; 27: 530–4.
10. Van Ede AE, Laan RF, Blom HJ, De Abreu RA, van de Putte LB. Methotrexate in rheumatoid arthritis: an update

- with focus on mechanisms involved in toxicity. *Semin Arthritis Rheum* 1998; 27: 277–92.
11. Rau R. Methotrexate therapy in rheumatoid arthritis. *Rheum Europe* 1994; 23: 60–5.
  12. Boerbooms AM, Kerstens PJ, van Loenhout JW, van Loenhout JW, Mulder J, van de Putte LB. Infections during low-dose methotrexate treatment in rheumatoid arthritis. *Semin Arthritis Rheum* 1995; 24: 411–21.
  13. Van Ede AE, Laan RF, Rood MJ, Huizinga TW, van de Laar MA, van Denderen CJ et al. Effect of folic or folinic acid supplementation on the toxicity and efficacy of methotrexate in rheumatoid arthritis: a forty-eight week, multicenter, randomized, double-blind, placebo-controlled study. *Arthritis Rheum* 2001; 44(7): 1515–24.
  14. Moller B, Kukoc-Zivojnov N, Okamgba S, Kessler U, Puccetti E, Ottmann OG et al. Folinic acid antagonizes methotrexate-induced differentiation of monocyte progenitors. *Rheumatol Int* 2002; 22(2): 60–7.
  15. Chaitov RM, Pinegin BV. Modern immunomodulators: basic principles of their application. *Immunology* 2005; 4–7 (in Russian).
  16. Abshalumov AS. The use of preparation Derinat in complex therapy of patients with various diseases. In: Materials of 1<sup>st</sup> All-Russian Conference “The use of preparation Derinat in various fields of medicine”. 22–24 May, Moscow, 2000: 33–6 (in Russian).
  17. Derinat – a unique Russian immunomodulator. EN Kaplina, ed. CJS FP “Technomedservis”, Moscow, 2000: 1–41 (in Russian).
  18. Gromov MI, Pivovarova LP. Use of immunomodulator derinat in the treatment of patients with surgical sepsis in traumatic shock. *Vestn Khir Im II Grek* 2002; 161(6): 45–8 (in Russian).
  19. Shchukin SA, Lipin AV, Rubinov LP. Experience of the use of preparation Derinat in children surgery clinics. In: Materials of 1<sup>st</sup> All-Russian Conference “The use of preparation Derinat in various fields of medicine”. 22–24 May, Moscow, 2000: 11–4 (in Russian).
  20. Sviatkina OI, Balashov VP, Balykova LA, Shchukin SA. Anti-arrhythmia activity of Derinat in an experiment. *Eksp Klin Farmakol* 2004; 67(1): 22–4 (in Russian).
  21. Kaplina EN. Some results of clinical use of preparation Derinat since 1976 till 2000. In: Materials of 1<sup>st</sup> All-Russian Conference “The use of preparation Derinat in various fields of medicine”. 22–24 May, Moscow, 2000: 3–6 (in Russian).
  22. Chernyshova ML. Complex treatment of viral hepatitis C by the use of extracorporeal methods of therapy and preparation Derinat. In: Materials of 1<sup>st</sup> All-Russian-Wide Conference “The use of preparation Derinat in various fields of medicine”. 22–24 May, Moscow, 2000: 36–42 (in Russian).
  23. Phillips CA, Cera PJ, Mangan TF, Newman ED. Clinical liver disease in patients with rheumatoid arthritis taking methotrexate. *J Rheumatol* 1992; 19(2): 229–33.
  24. Theisen-Popp P, Müller-Paddinghaus R. Antirheumatic drug profiles evaluated in the adjuvant arthritis of rats by multiparameter analysis. *Agents Actions* 1994; 42: 50–5.
  25. Caparroz-Assef SM, Bersani-Amado CA, do Nascimento EA, Kelmer-Bracht AM, Ishii-Iwamoto EL. Effects of the non-steroidal inflammatory drug nimesulide on energy metabolism in livers from adjuvant-induced arthritis in rats. *Res Commun Mol Pathol Pharmacol* 1998; 99(1): 93–116.
  26. Ranganathan P, Eisen S, Yokoyama WM, McLeod HL. Will pharmacogenetics allow better prediction of methotrexate toxicity and efficacy in patients with rheumatoid arthritis? *Ann Rheum Dis* 2003; 62(1): 4–9.
  27. Kollias G, Douni E, Kassiotis G, Kantoyiannis D. The function of tumour necrosis factor and receptors in models of multi-organ inflammation rheumatoid arthritis, multiple sclerosis and inflammatory bowel disease. *Ann Rheum Dis* 1999; 58 (Suppl 1): 132–9.
  28. Beutler BA. The role of tumour necrosis factor in health and disease. *J Rheumatol* 1999; 26 (Suppl 57): 16–21.
  29. Neurath MF, Hildner K, Becker C, Schlaak JF, Barbulescu K, Germann T et al. Methotrexate specifically modulates cytokine production by T cells and macrophages in murine collagen-induced arthritis (CIA): mechanism for methotrexate-mediated immunosuppression. *Clin Exp Immunol* 1999; 115(1): 42–55.
  30. Seitz M, Loetscher P, Dewald B, Towbin H, Rordorf C, Gallati H et al. Methotrexate action in rheumatoid arthritis: stimulation of cytokine inhibitor and inhibition of chemokine production by peripheral blood mononuclear cells. *Br J Rheumatol* 1995; 34(7): 602–9.
  31. Seitz M. Molecular and cellular effects of methotrexate. *Curr Opin Rheumatol* 1999; 11(3): 226–32.
  32. Constantin A, Loubet-Lescoulie P, Lambert N, Yassine-Diab B, Abbal M, Mazieres B et al. Antiinflammatory and immunoregulatory action of methotrexate in the treatment of rheumatoid arthritis: evidence of increased interleukin-4 and interleukin-10 gene expression demonstrated in vitro by competitive reverse transcriptase-polymerase chain reaction. *Arthritis Rheum* 1998; 41(1): 48–57.
  33. Wascher TC, Hermann J, Brezinschek R, Brezinschek HP, Wilders-Trusching M, Rainer F et al. Serum levels of interleukin-6 and tumour-necrosis-factor-alpha are not correlated to disease activity in patients with rheumatoid arthritis after treatment with low-dose methotrexate. *Eur J Clin Invest* 1994; 24(1): 73–5.
  34. May C, West SG, McDermott MT, Huffer WE. The effect of low-dose methotrexate on bone metabolism and histomorphometry in rats. *Arthritis Rheum* 1994; 2: 201–6.
  35. Jackson CG, Williams HJ. Disease-modifying antirheumatic drugs. Using their clinical pharmacological effects as a guide to their selection. *Drugs* 1998; 56: 337–44.
  36. Getov I, Dimitrova Z, Petkova V. Low dose treatment with methotrexate – adverse drug reactions survey. *Bull Chim Farm* 2000; 139(4): 153–8.



**Laima Leonavičienė, Eiva Bernotienė, Rūta Bradūnaitė,  
Dalia Vaitkienė, Elvyra Redaitienė, Vytautas Astrauskas**

**DERINATO ANTIARTRITINIO IR  
HEPATOPROTEKČINIO POVEIKIO ĮVERTINIMAS  
ŽIURKIŲ ADJUVANTINIAM ARTRITUI**

**S a n t r a u k a**

**Tikslas.** Nustatyti imunomodulatoriaus derinato (D) galimą antiartritinį poveikį, kai skiriamas jis vienas ir derinamas su metotreksatu (MTX), palyginti gautus rezultatus su vieno MTX poveikiu ir įvertinti D galimybes mažinant MTX hepatotoksiškumą.

**Medžiaga ir metodai.** 60 Wistar veislės žiurkių su adjuvantiniu artritu (AA) buvo gydytos D (6 mg/kg ir 18 mg/kg

dozės), MTX (2 mg/kg) ir jų deriniais. MTX kartą per savaitę ir D 5 kartus per savaitę buvo leidžiama į raumenis. Kontrolinės grupės gyvūnams su AA buvo leidžiamas fiziologinis tirpalas. Eksperimento trukmė – 17 dienų.

**Rezultatai:** Sąnarių patinimas ir histologiniai artrito rodikliai buvo statistiškai reikšmingai slopinami naudojant visus gydymo būdus. D efektyviausiai slopino TNF $\alpha$  ir didino limfocitų blasttransformaciją. Nors MTX ir D derinio antiartritinis poveikis nebuvo stipresnis, negu naudojant monoterapiją MTX, tačiau pastebėtas mažesnis kepenų pažeidimas.

**Išvados.** Mūsų rezultatai rodo, kad D mažina uždegimą ir AA požymius panašiai kaip ir nedidelės MTX dozės. D taip pat mažina MTX toksinį poveikį kepenims, kai jie vartojami kartu.

**Raktažodžiai:** adjuvantinis artritas, derinatas, metotreksatas